DOCUMENTS RELATED TO AGENDA ITEM IV:

Supplemental hazard identification materials for vinclozolin

NOTE: The documents included in this attachment are or may be protected by United States or foreign copyright laws. They are being provided to you for non-commercial, scientific or educational purposes only. To obtain permission to use these materials for other purposes, please contact the copyright owner.

In: Pathobiology of the Aging Rat. Vol 1 U. Mohr, D.L. Dungworth and C.C. Capen (eds) ILSI Press, Washington DC, 1992, pp. 443-467

Lesions in the Male Accessory Sex Glands and Penis

Maarten C. Bosland

Introduction

Most spontaneously occurring lesions in the accessory sex glands of the aging male rat are infrequent. Inflammation, atrophy, and, in the prostate, corpora amylacea are the only frequently observed spontaneous changes. Proliferative lesions are also rare, with the exception of atypical hyperplasia of the ventral prostate lobes, which occurs with variable incidence in many rat strains (Bosland 1987c). Nonneoplastic and neoplastic lesions of the urethra, penis, and prepuce are very uncommon. The purpose of this chapter is to provide the following information: (a) changes in accessory sex gland weights with aging; (b) concise descriptions of lesions that occur in the male accessory sex glands and penile structures of the aging rat, with emphasis on the most frequently found changes; (c) criteria to distinguish between hyperplastic and neoplastic lesions, and between benign and malignant neoplasms, with emphasis on proliferative lesions in the prostate; mesenchymal tumors of the accessory sex glands are discussed separately; (d) information about the pathogenesis and biologic significance of these lesions; and (e) interstrain variability and time dependence of occurrence of nonneoplastic and neoplastic lesions, with special attention to the F344, Sprague-Dawley, and Wistar rat strains.

Detection, and thereby incidence, of male accessory sex gland lesions is subject to several sources of bias. First, sampling and processing of the tissue may introduce inaccuracy and variation. Many standard protocols for toxicity and carcinogenicity testing only state that "the prostate and seminal vesicle" are to be examined (NTP 1984; OECD 1981; US EPA 1983; US FDA 1982), but do not give any detail about which part(s) of these tissues should be examined. Because of the extraordinary complexity of the male accessory sex gland structures, knowledge of their anatomic relationships and incorporation of this information in standardization of sampling and processing protocols is imperative for high-quality histopathology of the male genital tract. Second, the anatomic complexity of the accessory sex glands discourages a uniform histopathologic evaluation and may thereby introduce inter- and intraobserver bias. This chapter is intended to contribute to elimination of both types of bias. Therefore, anatomic considerations and suggestions for standardization of methods of examination of the rat male accessory sex glands will be discussed first.

Anatomic Considerations and Methods of Examination

As discussed in the previous chapter by Aumüller and Sinowatz, the rat male accessory sex glands[1] consist of the multilobulated prostate, the ampullary glands, and the seminal vesicles, which have intricate structural relationships. Other accessory sex glands, including the bulbourethral

[1]The nomenclature of the male accessory sex glands that is used in this chapter is largely according to Jesik et al. (1982); see also Aumüller and Sinowatz (this volume).

gland and periurethral glands, are anatomically distinct from the aforementioned glands, and they are usually not routinely examined in toxicity or carcinogenicity testing studies. The rat prostate, which is of urogenital sinus origin (Price 1963), consists of four paired lobes (Aumüller and Sinowatz, this volume; Jesik et al. 1982; Lee and Holland 1987; Price 1963): the ventral, dorsal, lateral, and anterior lobes. The anterior prostate, which is usually referred to as the coagulating gland, extends parallel to the wolffian duct-derived (Price 1963; Thiedemann 1987) seminal vesicles. The dorsal and lateral lobes are often referred to as dorsolateral prostate, because it is difficult to distinguish between these lobes on a routine basis. Nevertheless, it is possible to grossly and microscopically distinguish lateral and dorsal prostate (Jesik et al. 1982; Lee and Holland 1987). These prostate lobes are morphologically similar (Jesik et al. 1982; Lee and Holland 1987) and often display a comparable spectrum of pathologic changes in the aging rat (Bosland 1987a, b, c). The ventral lobe, on the other hand, is anatomically distinct (Jesik et al. 1982; Lee and Holland 1987) and shows a spectrum of lesions that may differ from that found in the dorsolateral prostate (Bosland 1987a, b, c). The tissues that directly surround the prostatic urethra and prostatic utricle are structurally very complex since they consist of the ducts of the four prostate lobes and the seminal vesicles, as well as the wolffian duct-derived (Thiedemann 1987) deferent ducts and ampullary glands.

Correct tissue processing methods, in particular tissue trimming, are critical in the microscopic evaluation of rat accessory sex glands, as indicated earlier. Because of the structural complexity of the rat male accessory sex glands it is imperative to vigorously standardize tissue trimming methods, which will provide the pathologist consistently with the same orientation of the tissue and thereby reduce intraobserver bias. The accessory sex structures are best removed and fixed in toto together with the urethra and urinary bladder (the latter can be removed for separate fixation if required). One tissue trimming method has been described previously (Bosland 1987c). Briefly, it consists of cutting the dorsolateral prostate complex in halves at a right angle to the prostatic urethra after trimming off the urinary bladder, ventral prostate lobes, and seminal vesicle/coagulating complexes. These dorsolateral prostate lobe halves are both embedded and sections will show dorsal and lateral prostate, ampullary glands, prostatic urethra, and prostatic utricle, as well as ducts of the prostate lobes, coagulating glands, and seminal vesicles; the ventral lobes are separately embedded. Alternatively, it is possible to make sections in a parasagittal plane including dorsolateral lobes and some of the ampullary glands, and, in smaller rats, ventral lobes; the periurethral region cannot easily be viewed in this approach. The coagulating glands and seminal vesicles are best viewed together, and a longitudinal section is preferable to a cross-section because there are proximal-distal differences in the occurrence of proliferative lesions in the seminal vesicle. Although it may not be necessary to distinguish between ventral and dorsolateral prostate on a routine basis in toxicologic pathology, it is important to include both ventral and dorsolateral prostate in microscopic examination of the rat male genital tract, whichever tissue trimming method is used, so that the exact lobe localization of lesions can be determined when required.

Changes in Organ Weights with Aging

It is difficult to judge the value and reliability of reported accessory sex gland weights because they vary greatly depending on the method by which the tissue was dissected at autopsy. For example, unless the dissection methodology is accurately described, the weight of "the prostate" cannot be interpreted. The ventral prostate can easily be separated and freed from surrounding fat tissue by blunt dissection, and rather accurate ventral prostate weights can thus be obtained without jeopardizing histologic integrity of the tissue. Dissection of the dorsolateral prostate, coagulating glands, and seminal vesicles for weighing purposes is a much more complicated, but not impossible (Lee and Holland 1987), proposition for the following reasons. The contents usually spill from the coagulating glands and seminal vesicles directly after they are cut

from the dorsolateral prostate, affecting weight and size, and thereby histologic appearance, particularly of the seminal vesicles. In addition, it is difficult to standardize the site at which these structures are removed from the dorsolateral prostate, although it is rather easy to dissect coagulating gland from seminal vesicle. For these reasons, it is not possible to compare accessory sex gland weights between studies, and there is virtually no reliable information on changes in accessory sex gland weights with aging in different rat strains. Data on ventral prostate weights (unspecified dissection methodology) in COP and ACI/SegHap rats (Isaacs 1984) suggest that the absolute weight of this lobe increases considerably until 12 months of age in a steady fashion, with the most rapid increase during the first 4 months of life. Subsequently, ventral prostate weight decreases slowly from age 12–16 months onward, without a concomitant comparable decrease in body weight. The fastest rise in weight of the ventral prostate, and for that matter all other accessory sex glands, takes place during puberty, i.e., between 4 and 6–7 weeks of age (Stiens and Helpap 1981a).

The most practical approach to studying accessory sex gland weights is to establish a vigorously standardized but easy-to-apply method for dissecting the structures of interest, and to determine baseline values using this method in the rat strain under study. An easy, yet accurate, way to obtain a measure of accessory sex gland weights is to remove them in toto, subsequently remove the bladder and all but the intraprostatic part of the urethra, and weigh them together after cleaning connective tissue away. The ventral lobes can also be removed prior to weighing. Removal of the intraprostatic urethra interferes with further histologic examination of the dorsolateral prostate-ampullary gland complex and creates the risk of considerable spillage of seminal vesicle secretion.

Prostate

The rat prostate, as mentioned earlier, has four distinct paired lobes. A distinction between the various lobes is not always made, even in research specifically directed to the prostate. Although in general it would be prudent to discriminate between prostate lobes, in routine toxicologic pathology, this is, with the exception of the anterior prostate (coagulating gland), neither practicable nor necessary. Only when treatment-related effects are suspected to occur is it desirable to determine the exact lobe localization of lesions. The coagulating gland is easily distinguishable from the other prostate lobes; it is usually embedded together with the seminal vesicle, and the structure of this gland and its spectrum of pathologic changes are different from those of the other prostate lobes. Therefore, it is advisable to treat the coagulating gland as a separate tissue for routine purposes. This gland will also be discussed here separately, whereas the ventral and dorsolateral prostate lobes are considered together.

Differences in the occurrence of neoplastic and nonneoplastic prostate lesions between different rat strains have been reported by Isaacs (1984) for the COP and ACI/SegHap strains and by Burek (1978) for the WAG/Rij and BN/Bi strains and their F1 hybrid. Isaacs (1984) demonstrated marked strain differences in the incidence of various lesions in the ventral prostate with aging, in terms of both time to onset and final incidence. Burek (1978) found distinct strain differences in the frequency and age at observation of severe suppurative inflammation with abscess formation in the prostate (n.o.s., not otherwise specified) of aged rats. These studies emphasize that marked strain differences in the occurrence of prostate lesions do exist, since husbandry conditions and methods of examination were kept constant. Unfortunately, none of the strains in these studies are commonly used in toxicity and carcinogenicity testing. Therefore, no further details are presented here, and the interested reader is referred to the original publications (Burek 1978; Isaacs 1984).

Data on the incidence of accessory sex gland lesions in large numbers of animals are limited to the 2- to 2 1/2-year age range, whereas studies of younger ages mostly concern small numbers of rats. This chapter includes the most recent incidence data available for the F344 strain (from the National Toxicology Program, NTP), the Sprague-Dawley strain (unpublished data from Merck Sharp and Dohme Research Laborato-

ries, West Point, PA), and Wistar rats (unpublished data from Hoechst AG, Frankfurt, Germany, and the TNO-CIVO Toxicology and Nutrition Institute, Zeist, The Netherlands). The few studies that have directly compared changes in lesion incidences with aging between rat (sub)strains (Isaacs 1984; Kroes et al. 1981) are also discussed, but studies dating from before 1975 are not included. Incidences of nonneoplastic and neoplastic lesions are summarized in Tables 1 and 2 (F344), 3 and 4 (Sprague-Dawley), and 5 and 6 (Wistar).

Nonneoplastic Lesions

Inflammation

Inflammation is the most frequently occurring lesion in the rat prostate (Tables 1–6). All types and all stages of inflammation can be found, varying from acute inflammatory lesions with a predominant polymorphonuclear infiltrate and a suppurative character, to chronic types of inflammation with interstitial mononuclear infiltrate, proliferative inflammatory changes, and/or granuloma development, to abscess formation. A frequent finding is prostatic acini or ducts filled with cellular debris and polymorphonuclear inflammatory cells, but with unchanged epithelium and surrounding interstitium. This is probably due to an acute inflammatory process located peripherally in the same tubuloalveolar prostatic gland unit. Acute inflammation can vary from a small area of affected glandular epithelium with neutrophilic infiltration and some epithelial degeneration and sloughing (Fig. 1) to involvement of an entire prostate lobe with massive suppuration. Sometimes only a single tubuloalveolar unit is affected from the periphery to the opening of the duct in the urethra (Fig. 2), perhaps suggesting that an infectious agent has penetrated from the urethra into this unit, but not into neighboring ones. In aged rats, all stages of postinflammatory repair can be found, as prostatitis often is not an end-stage disease.

"Spontaneous" prostatitis may or may not be associated with bacterial infection (Müntzing et al. 1979). It often predominates in the lateral prostate, and the ventral prostate is probably the least frequently affected lobe (Müntzing et al. 1979), but exact information on lobe preference is lacking for most rat strains. Prostatitis can be induced by intravesicular inoculation of pathogenic bacteria, leading to inflammation in the ventral prostate in young rats (Friedlander and Braude 1972) that lack antibacterial substances in this lobe (Levy and Fair 1973). However, inoculation of pathogenic bacteria into a ventral prostate lobe causes inflammation not only in the ventral but also in the dorsal and lateral lobes (Kaplan et al. 1983), indicating that infection can spread from one lobe to another. Castration enhances the incidence and severity of spontaneous lateral prostate inflammation (Lundgren et al. 1984) and increases persistence of induced inflammatory changes in all lobes (Kaplan et al. 1983). Testosterone administration in intact rats has little effect on the development of spontaneous prostatitis in the lateral lobe (Lundgren et al. 1984); however, combined treatment with estrogens and androgens induces inflammation predominantly in the lateral prostate (Leav et al. 1988, 1989; Robinette 1988). Thus, these hormones may be related to the propensity of this lobe to develop inflammatory changes. Prolactin secretion is stimulated by estrogen and is perhaps also involved since the lateral prostate seems more sensitive than the two other lobes to the combined action of this hormone and testosterone (Lee and Grayhack 1989). Stress (low temperature, limited space, and access to water and food) has been shown to produce by an unknown mechanism nonbacterial inflammatory changes within 3–10 days, which were marked in the ventral lobe but mild in the dorsolateral prostate (Aronsson et al. 1988; Gatenbeck et al. 1987). In comparison with rats separated by sex, continued opportunity for sexual activity reduces the incidence and severity of spontaneous inflammatory lesions in the lateral prostate (Aumüller et al. 1987; Lundgren et al. 1984). Aumüller et al. (1987) proposed that stagnant secretion containing cellular debris from desquamated cells interacting with a secretory protein that is specific for the lateral prostate causes the age-related spontaneous inflammation in that lobe in animals that are kept under celibate conditions.

There is probably no correlation between prostatitis and the presence of inflammatory lesions

Table 1. Incidence (%) of nonneoplastic and neoplastic lesions in the prostate of 25- to 26-month-old F344 rats[a]

	Reference				
	NTP Reports[b]	Goodman[c]	Reznik[d]	Charles River[e]	Solleveld[f]
No. of animals	994	1754	1775	938	2320
Inflammation					
N.o.s.	NA	9			
Acute	12 (0–38)	NA			
Chronic	17 (0–69)	NA			
Atrophy (n.o.s.)	0.1 (0–2)	0.9			
Hyperplasia (n.o.s.)	6 (0–23)	1.4	2.8[g]		
Corpora amylacea/ concretions	0.3 (0–4)	0			
Adenoma	0.2 (0–2)	0.17	3.6[g]	0.3 (0–1.6)	0.6
Adenocarcinoma	0	0	0.4[g]	0	0
Malignant schwannoma	0.1 (0–2)	0	0	0	0
Paraganglioma	0	0.05	0	0	0

NA, not applicable

[a] This table does not include a study of 296 27- to 30-month-old F344/DuCrj rats that did not have any prostate neoplasms (Maekawa et al. 1983).

[b] Data for control F344/N rats from 21 NTP carcinogenicity studies (1989 Technical Report Nos. 345, 356–367, 369, 370; 1990 Technical Report Nos. 372–376, 378, 379); range is given in parentheses.

[c] Data on unspecified substrain reported by Goodman et al. (1979).

[d] Data only on proliferative lesions in unspecified substrain reported by Reznik et al. (1981).

[e] Control tumor data for CDF (F344/Crl) rats from 13 studies (Charles River Laboratories 1990); range is given in parentheses.

[f] Control tumor data for F344/N rats (Solleveld et al. 1984); this study also included 529 F344/N rats kept for life, none of which developed prostate tumors.

[g] All lesions were found in the ventral prostate.

Table 2. Incidence (%) of nonneoplastic lesions in the prostate of 6- to 33-month-old F344 rats[a]

	Age period (months)				
	6–11	12–17	18–23	24–29	30–33
No. of animals	13	19	35	42	15
Inflammation					
Acute	31	26	20	17	20
Chronic	31	47	43	31	20
Atrophy (n.o.s.)	0	0	0	2	0

[a] Adapted from study of unspecified substrain reported by Coleman et al. (1977). No tumors or hyperplastic lesions of the prostate were reported.

at other sites, such as the respiratory tract (M.C. Bosland, unpublished data), but no definitive information is available in this regard. The occurrence of prostatitis may be associated with infection pressure from outside, since a high prevalence of prostatic inflammation is sometimes recurrently found in specific animal rooms, but not in others (M.C. Bosland, unpublished data). Thus, the presence of prostatitis as a postmortem observation may serve as a health status indicator. Only very severe inflammation can lead to or contribute to the death or moribund state of aged rats, particularly when other pathologic conditions exist that weaken the animal.

The incidence of inflammatory lesions in the rat prostate is rather variable, both within one strain (Tables 4, 6) and between strains (Tables 1–6). It is not clear to what extent interobserver bias is responsible for this variability. The very large range in the incidence of prostatitis in control groups of F344/N rats in 21 recent 2-year studies completed within a 3-year period for the NTP by 11 different testing laboratories (Table

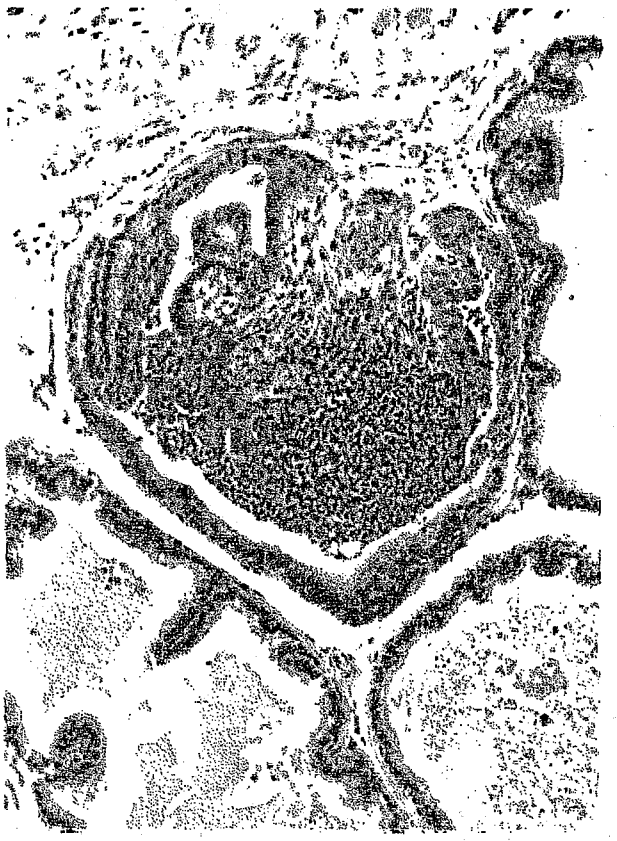

Fig. 1. Minimal focal acute inflammation, dorsal prostate. H&E, × 135

Fig. 2. Acute inflammation limited to one tubuloalveolar unit of the lateral prostate. H&E, × 28

1) suggests that differences in environmental conditions between laboratories as well as interobserver differences in scoring of inflammatory lesions play a role in this regard. Information about differences in occurrence of inflammation between ventral and dorsolateral prostate is only available for Wistar rats (Table 6). In this strain there is an age-related increase in the incidence of acute and chronic inflammatory lesions (Table 5) which are more prevalent in the ventral than the dorsolateral prostate (Table 6). Such an association with age is not apparent from data for the F344 and Sprague-Dawley strains (Tables 2–4). For practical purposes it is useful to limit the types of inflammation in toxicity testing reports to acute and chronic inflammation, and perhaps interstitial accumulation of mononuclear inflammatory cells. Focal inflammatory lesions can be graded on the basis of a combination of the number and size of the inflammatory foci and the severity of the inflammation, whereas diffusely occurring inflammation can be graded primarily according to severity.

Atrophy

Three forms of atrophic change can be distinguished in the rat prostate. One is diffuse atrophy that results from androgen deprivation and is found after castration or testicular atrophy. There is hyposecretion and a loss of epithelial cells without concomitant cell renewal, the epithelial cells take on an undifferentiated morphology with few secretory features, and the amount of fibromuscular stroma is apparently increased. The result is a decrease in glandular size and weight. This type of atrophy can occur in any of the prostate lobes. The second form of atrophy consists of a marked flattening of the epithelium in most alveoli without much loss of secretory material or increased amount of stromal tissue, suggesting a decreased rate of glandular emptying resulting in cessation of secretory activity. This type of diffuse atrophy is most often found

Table 3. Incidence (%) of nonneoplastic and neoplastic lesions in the prostate of 1.5- to 46-month-old Sprague-Dawley rats

	Age period (months)				
	1.5–4.5	4.6–7.5	7.6–13.5	13.6–46	25
No. of animals	1707[a]	434[a]	417[a]	1986[a]	869[b]
Inflammation					
N.o.s.	3	5	7	10	
Mononuclear infiltrate	10	14	3	0.4	
Atrophy (n.o.s.)	0.5	16	1.4	1.5	
Hyperplasia (n.o.s.)	0.5	0	0.7	3	
Corpora amylacea/ mineralization	0	1.8	0	0.3	
Adenoma	0	0	0	0.3	0
Adenocarcinoma	0	0	0	0.2	0.5 (0–1.4)
Histiocytic sarcoma	0	0	0	0.2	0
Sarcoma (n.o.s.)	0	0	0	0.2	0
Fibrosarcoma	0	0	0	0	0.1 (0–1.3)
Leiomyosarcoma	0	0	0	0	0.1 (0–1.3)

[a] Unpublished data for control Crl:CD(SD) rats from Merck, Sharp and Dohme Research Laboratories, West Point, PA, 1969–1988.
[b] Tumor data for control Crl:CD rats from 13 studies (Charles River Laboratories 1987); range is given in parentheses.

Table 4. Incidence (%) of nonneoplastic lesions in the prostate of 6- to 38-month-old Sprague-Dawley (Hap:SD and Crl:CD) rats[a]

	Age period (months)					
	6–11	12–17	18–23	24–29	24–29	30–33
Strain[b]	Hap	Hap +CD	Hap +CD	Hap	CD	CD
No. of animals	13	26	20	32	25	43
Inflammation (n.o.s.)	23	15	5	44	25	21
Atrophy (n.o.s.)	0	0	0	0	0	7
Hyperplasia						
Atypical	0	0	0	3	0	0
Reactive	0	0	10	34	12	16
Corpora amylacea/ mineralization	46	62	50	78	20	37

[a] Adapted from Anver et al. (1982); no neoplasms of the prostate were seen.
[b] Hap, Hap:SD substrain; CD, Crl:CD substrain

in the ventral prostate of aging rats (Isaacs 1984). The third form of atrophy is a focal atrophic lesion of the castration atrophy type, usually with a pronounced sclerotic reaction. This focal sclerotic atrophy is probably the end-result of an earlier focal inflammatory lesion and can occur in any of the prostate lobes.

An increased occurrence of diffuse atrophy (second type) and decreased wet weight of the ventral prostate with aging is correlated with decreases in serum testosterone levels in the COP and ACI/SegHap strains (Isaacs 1984). On the other hand, there is no correlation between the occurrence of bilateral testicular atrophy and the presence of atrophy (any type) of any of the prostate lobes in Wistar (Cpb:WU strain) rats (M.C. Bosland, unpublished data). There is also no correlation for the presence of marked diffuse

Table 5. Incidence (%) of nonneoplastic and neoplastic lesions in the prostate of 24- to 30-month-old Wistar (Hoe:Wiskf/SPF71) rats[a]

	Age period (months)	
	24–26 (10 studies)	27–30 (12 studies)
No. of animals	522	790
Inflammation (n.o.s.)	4 (1–6)[b]	9 (3–16)
Atrophy (n.o.s.)	0	1.9 (1.7–2)

[a] Data for control rats from Hoechst AG, Frankfurt, Germany, 1982–1990; No neoplasms were observed.
[b] Range is given in parentheses.

Table 6. Incidence (%) of nonneoplastic and neoplastic lesions in the prostate of 4- to 33-month-old Wistar rats

Reference	Bosland[a]				Kroes et al.[b]		
Substrain	Cpb:WU					Cpb:WU	Tox:WU
Age (months)	4	13	25	33	25–33	>18	>30
No. of animals					3861[c]	143	67
No. of tissues (VP, DLP)[d]	45, 21	44, 31	62, 50	37, 43			
Inflammation							
N.o.s.[d]						3	31
Acute[d]	7, 0	9, 23	11, 26	19, 58			
Chronic[d]	0, 0	2, 10	7, 12	16, 30			
Atrophy, diffuse[d]	0, 0	0, 0	2, 6	5, 16		0	0
Hyperplasia, atypical[d]	0, 0	5, 0	16, 0	24, 0		0	0
Corpora amylacea/ concretions[d]	0, 5	66, 65	89, 66	92, 16		0	0
Squamous metaplasia[d]	0, 0	0, 0	0, 0	0, 0		0	4
Adenoma					0.03[e]	0	0
Adenocarcinoma					0.03[f]	0.7	0

[a] M.C. Bosland, unpublished data for control Cpb:WU rats.
[b] Data from control Cpb:WU and Wistar SPF Tox (Tox:WU) rats reported by Kroes et al. (1981).
[c] Number of Cpb:WU rats for which tumor data were available (TNO-CIVO Toxicology & Nutrition Institute, Zeist, The Netherlands, 1976–1987).
[d] Nonneoplastic lesion incidences are given separately for the ventral prostate (VP) and dorsolateral prostate (DLP).
[e] Originated from ventral lobe.
[f] Originated from dorsolateral lobe.

atrophy between different prostate lobes and other accessory sex glands in this strain. Treatment-induced testicular atrophy, however, is usually accompanied by diffuse atrophy of all accessory sex glands. Thus, although drug- or castration-induced androgen deprivation results in prostatic atrophy, there are apparently also other mechanisms by which diffuse atrophy can develop in one or more prostate lobes.

The spontaneous incidence of atrophy (n.o.s.) of the prostate (n.o.s.) is not high in F344, Sprague-Dawley, and Wistar rats (Tables 1–6). In most available data sets this change becomes somewhat more frequent with aging. However, this does not universally occur, as indicated by the incidence data for Sprague-Dawley rats in Table 3, showing a ten-fold higher incidence in 4.5- to 7.5-month-old animals than in either younger or older rats. In the Wistar rat atrophy occurs more frequently in the dorsolateral than in the ventral prostate (Table 6). The data on ventral prostate atrophy in COP and ACI/SegHap rats indicate that there can be considerable strain differences in time to onset and final incidence of

Fig. 3. Focal squamous metaplasia and large concretion blocking a duct, dorsolateral prostate. H&E, × 135

diffuse atrophy (Isaacs 1984). Focal atrophic lesions can be graded on the basis of a combination of the number and size of the atrophic foci and the severity of the atrophy, whereas diffuse atrophy can be graded only according to its severity.

Corpora Amylacea

Corpora amylacea can be found in the prostate of most aged rats, but their abundance varies greatly (M.C. Bosland, unpublished data). These concretions often undergo some degree of mineralization when they become larger and more abundant. There is no association with inflammatory changes (Table 6; Isaacs 1984; M.C. Bosland, unpublished data). Occasionally corpora amylacea in the dorsolateral prostate become so large that they block excretory ducts and cause local squamous metaplasia and/or inflammatory reaction (Fig. 3). The increasing incidence of concretions in the ventral prostate with aging coincides with the occurrence of atypical hyperplasia in at least some rat strains (Isaacs 1984), but there is no correlation between their presence and atypical hyperplastic lesions in individual ventral lobe alveoli in Wistar rats (M.C. Bosland, unpublished data). The pathogenesis of corpora amylacea in the rat prostate is not known.

The occurrence of corpora amylacea is probably an age-related phenomenon in most rat strains (Tables 4, 6; Isaacs 1984). Interestingly, the frequency of these concretions steadily increases with age in the ventral prostate of Wistar rats, but not in the dorsolateral lobe, where their prevalence appears to decrease after 25 months of age (Table 6). The incidence of corpora amylacea is rather variable among different studies (Tables 1–6), likely in large part due to differences in criteria used to make a decision on whether or not to record their presence. Nevertheless, the occurrence of this change can vary greatly between (sub)strains (Table 4; Isaacs 1984). The presence of corpora amylacea can be graded on the basis of the number of alveoli with concretions and the amount of corpora in the afflicted alveoli.

Hyperplasia

There are basically four distinct types of hyperplasia in the rat prostate, reactive hyperplasia and three types of nonreactive hyperplastic lesions (Bosland 1987). *Reactive hyperplasia* is always combined with inflammatory cell infiltrate. It characteristically consists of a simple thickening of the epithelium into two to six or more cell layers, although pseudoglandular structures can be found. The hyperplastic cells may be slightly atypical but are mostly rather uniform. Reactive hyperplasia is most frequently found in the dorsolateral prostate, particularly the lateral lobe, and less often in the ventral prostate. Its incidence parallels that of prostatitis and is usually not separately recorded.

Functional hyperplasia can be (multi)focal or diffuse in both the ventral and the dorsolateral prostate. In the ventral prostate, functional hyperplasia is usually found at the periphery of the lobe, and it is characterized by crowded epithelial cells that are tall columnar and by increased infolding of the lining epithelium into the alveolar lumen. The cells are hyperbasophilic but otherwise normal. The amount of intra-alveolar

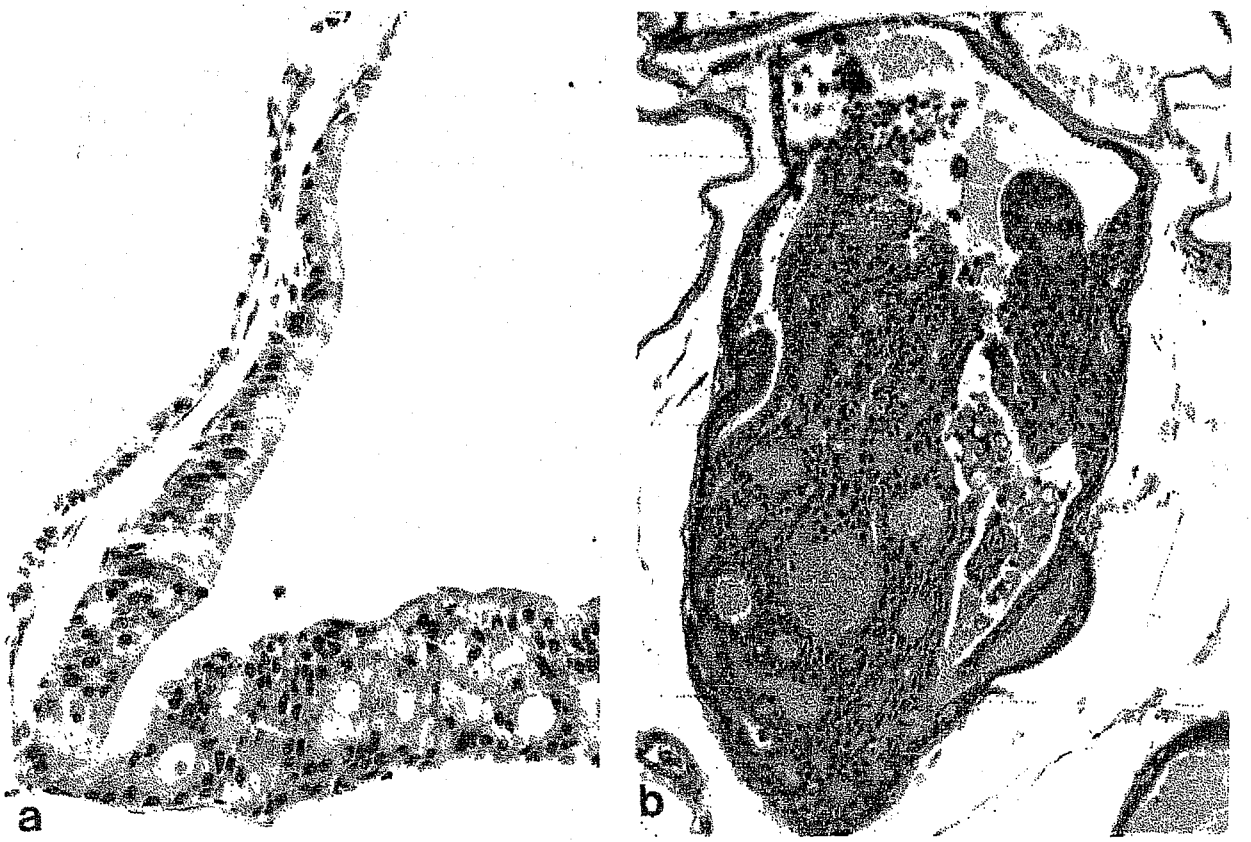

Fig. 4a, b. Atypical hyperplasia, ventral prostate. **a** Minimal atypical hyperplasia merging with normal epithelium. H&E, × 275. **b** Marked atypical hyperplasia confined to one acinus but almost obliterating the lumen. H&E, × 135

secretion is often decreased. In contrast to reactive or atypical hyperplasia, the epithelium is not multilayered, but the increased infolding can be mistaken for cribriform growth. Functional hyperplasia may be accompanied by diffuse enlargement of the gland in question, but enlargement of accessory sex glands is often the result of hypersecretion or obstruction of the outflow of secretory material rather than hyperplasia. A mild degree of functional hyperplasia is frequent in (young) adult rats, but its presence is rarely recorded as a spontaneous finding.

Atypical hyperplasia occurs in all male rat accessory sex glands, but is frequent only in the ventral prostate. Detailed descriptions of this focal intra-alveolar papillary/cribriform lesion of the *ventral prostate* (Fig. 4) have been published elsewhere (Bosland 1987c; Isaacs 1984; Reznik 1990; Reznik et al. 1981; Ward et al. 1980). The term "atypical hyperplasia" is favored by this author over synonyms such as "hyperplasia" or "dysplasia," because it captures the two essential elements of the lesion, i.e., hyperplasia and cellular/nuclear atypia. Focal dysplasia, i.e., regions with marked cellular atypia, can occur within areas of atypical hyperplasia, as can squamous metaplasia (Reznik et al. 1981). It is likely that the lesions designated as hyperplasia (n.o.s.) in Tables 1 and 3 were in fact atypical hyperplasia of the ventral prostate.

Since there is little doubt that adenoma of the ventral prostate develops from atypical hyperplasia and carcinoma from adenoma (Reznik et al. 1981; Ward et al. 1980), atypical hyperplasia should be regarded as preneoplastic (Bosland 1987a, b, c) and should be distinguished from other types of hyperplasia. Since all stages from very early hyperplasia to adenoma and carcinoma can be observed in ventral prostates from aged rats without a clear separation between these lesions, the development of ventral prostate carcinomas is probably a continuum without discrete steps (Bosland 1987a, b, c; Reznik et al. 1981; Ward et al. 1980). However, with increasing size of the proliferative lesions, there is an increase in the occurrence of focal dysplastic

Table 7. Morphologic criteria to distinguish between atypical hyperplasia, adenoma, and adenocarcinoma of the rat ventral prostate[a]

Morphologic feature	Atypical hyperplasia	Adenoma	Adenocarcinoma
Size	One to a few adjacent alveoli	One to several (<10) adjacent alveoli	>10 adjacent alveoli
Obliteration of alveolar lumen	No	Yes	Yes
Distortion of normal architecture	No	Yes	Yes (marked)
Compression of surrounding tissue	No	Yes	Yes
Capsule formation	No	Sometimes	Often marked and with fibroplasia
Growth pattern	Cribriform	Predominantly cribriform, also solid and comedo	Cribriform, solid and comedo
Central necrosis	No	No	Frequently
Inflammatory infiltrate	No	Occasionally	Frequently
Invasive growth	No	No	Yes
Degree of pleomorphism (atypia)	Mild	Mild to moderate	Moderate to marked

[a] Adapted in part from Mitsumori and Elwell (1988), and Bosland (1987a, b, c).

areas, and of comedo and solid growth patterns, while cellular atypia also increases slightly. This may be a morphologic expression of increased neoplastic and ultimately malignant potential. Distinction between hyperplasia, adenoma, and carcinoma of the ventral prostate thus poses considerable difficulty and is to some extent arbitrary. Since there is little insight into the biologic behavior of these proliferative lesions, standard morphologic criteria that are used for the distinction between hyperplasia and neoplasia in other organs of rodent species are best applied for the present time (Boorman 1985). A practical approach to distinguish adenoma from atypical hyperplasia in the ventral prostate is to reserve the term "atypical hyperplasia" for proliferations that do not completely obliterate the alveolar lumen and are limited to one to three adjacent alveoli, do not compress surrounding tissue, and do not disturb normal alveolar architecture (Table 7; see also Bosland 1987c; Mitsumori and Elwell 1988). Capsule formation and the presence of comedo growth patterns should be regarded as indicative of neoplasia.

The pathogenesis of atypical hyperplasia of the ventral prostate is not known. The lesion can be induced by some carcinogens, including low doses of cadmium (Katayama et al. 1982; Pour 1983; Pour and Stepan 1987; Shirai et al. 1986; Waalkes et al. 1988, 1989).

The incidence of atypical hyperplasia increases slightly with aging in probably all rat strains (Tables 3, 6; Isaacs 1984) but remains rather low, with the exception of the ACI/SegHap strain, in which almost 100% of animals have such lesions by 2 years of age (Isaacs 1984; Ward et al. 1980). Interobserver bias probably influences the recorded prevalence of this lesion to a great extent, as is suggested by the large range in incidence in the NTP studies with F344/N rats summarized in Table 1 and by the differences in incidence between studies with Wistar rats given in Table 6. Grading of atypical hyperplasia can be done on the basis of a combination of the number of alveoli affected and the extent of the lesions.

Atypical hyperplasia of the *dorsolateral prostate* is very rare. This lesion has not been reported to occur spontaneously, but only to result from treatment with chemical carcinogens and/or sex steroids (Bosland 1987c; Bosland et al. 1990; Leav et al. 1988, 1989; Shirai et al. 1991). There is considerable variation in the appearance of dorsolateral prostate atypical hyperplasia, which is described in some detail elsewhere (Bosland 1987c; Bosland et al. 1990). The lesion may vary from intra-alveolar microgland formation with atypical cells arranged in a single layer to multilayered areas consisting of disarranged, piled up, enlarged, hypochromatic cells with large pale nuclei, sometimes with a cribriform

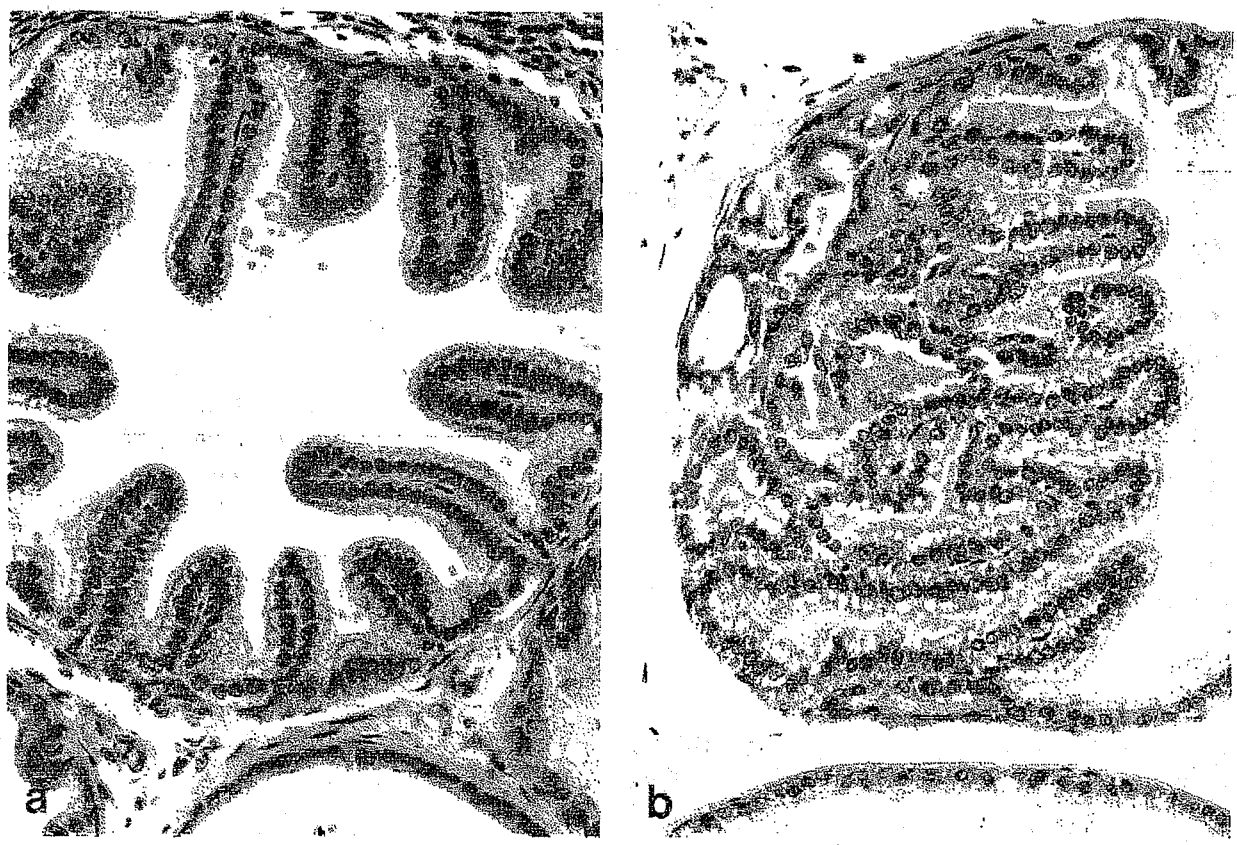

Fig. 5a, b. Seminal vesicle-like hyperplasia, dorsal prostate. **a** The acinus at the *top* has increased infolding and epithelium that is taller than the unchanged epithelium in the *lower right-hand corner*, and nuclei that are basally located. H&E, × 275. **b** The hyperplastic epithelium that protrudes into the acinar lumen is seminal vesicle-like with increased folding, and it is continuous with an area at the *left side* where the epithelium is atypical, with formation of some small glands. H&E, × 275

growth pattern (see also Leav et al. 1988, 1989). It can occur in the alveoli as well as in the ducts. It is difficult if not impossible to distinguish between atypical hyperplasia with a distinct inflammatory component and reactive hyperplasia as such, which occurs frequently in the (dorso) lateral prostate.

Seminal vesicle-like hyperplasia is a change that is characterized by the replacement of the normal epithelium of the dorsolateral prostate by epithelial cells that closely resemble seminal vesicle epithelium (Fig. 5). The cells in this lesion are columnar with somewhat elongated, strongly basophilic, basal nuclei. There is a distinct increase in the number of cells per unit length of basement membrane as compared with normal epithelium, and there is often an increase in the number of glandular infolds. Areas of atypical hyperplasia may occur in this lesion, and these atypical areas may be continuous with early-stage adenocarcinomas. This lesion is therefore perhaps a precursor of atypical hyperplasia, which is a potential preneoplastic lesion. This type of hyperplasia is uncommon as a spontaneous lesion in aging rats but can develop in response to exposure to chemical or hormonal carcinogens (M.C. Bosland, unpublished data; T. Shirai, personal communication).

Other Nonneoplastic Lesions

Squamous metaplasia is a proliferative change, as has been demonstrated, for example, in the dog prostate (Merk et al. 1986). Focal metaplastic changes of the prostate, occasionally with some keratinization, occur in aging rats often as a reaction to either the presence of large concretions in dorsolateral prostate ducts (Fig. 3) or inflammatory processes. Diffusely occurring squamous metaplasia has not been reported to occur spontaneously in the rat prostate. Squamous metaplasia is difficult to induce, but there is a report of production of this change by estro-

gen in the rat seminal vesicle and dorsolateral prostate ducts, but not the ventral prostate or coagulating gland (Ber and Levy 1952).

Other nonneoplastic lesions that have been observed in the rat prostate include fibrosis, edema, hemorrhage, epithelial degeneration, epithelial vacuolization, mucoid metaplasia, and cystic changes. Apoptosis is the mechanism of cell death in the rat prostate under normal and androgen-deprivation conditions (Kerr and Searle 1973; Stiens and Helpap 1981b). Increased occurrence of apoptotic bodies therefore indicates an increased rate of programmed cell death.

Neoplastic Lesions

Naturally occurring neoplasms of the rat prostate are rare. Most macroscopic changes that could be indicative of tumors, such as diffuse or nodular enlargements, are likely to be inflammation rather than neoplasia. Although some prostate tumors are visible at necropsy, microscopic tumors can also occur. Adenomas are microscopic, whereas some tumors, mostly carcinomas, are so large that it is difficult to determine from which accessory sex gland they originate. Macroscopically detectable ventral prostate carcinomas have been described in aging ACI/SegHap rats as hemorrhagic and pigmented nodular areas (Ward et al. 1980). Tumors of the dorsolateral prostate are typically located at the base of the seminal vesicle-coagulating gland complexes, leaving most of these free of tumor, unless the tumors are very large (Bosland 1987a; Bosland et al. 1990). Urinary obstruction, leading to hydronephrosis and death, is a common feature. Dorsolateral prostate carcinomas are firm and multinodular tumors, sometimes with central necrosis or hemorrhagic areas.

The incidence data summarized in Tables 1, 3, 5, and 6 indicate that neoplastic lesions of the rat prostate are uncommon in F344, in Sprague-Dawley, and particularly in Wistar rats. There is one report on F344 rats indicating a 3.6% incidence of adenomas of the ventral prostate (Reznik et al. 1981), which is about 10- to 15-fold that reported by others (Table 1; Solleveld et al. 1984; Goodman et al. 1979). However, if the incidence of all types of proliferative lesions is calculated, there are no differences between the study by Reznik et al. (1981) and the data from 21 recent NTP studies (6.8% and 6.2%, respectively; Table 1). Thus, there were probably major differences between these studies in criteria used to distinguish between hyperplasia, adenoma, and carcinoma, which emphasizes the need for standardization of these criteria.

Adenomas and adenocarcinomas of the rat prostate and precursor lesions thereof (atypical hyperplasia) can be induced selectively in the ventral lobe by a number of carcinogens (Katayama et al. 1982; Pour 1983; Pour and Stepan 1987; Shirai et al. 1986; Waalkes et al. 1988, 1989; see also Bosland 1987a, b, c). Induction of low incidences of dorsolateral prostate adenocarcinomas and precursor lesions can be achieved by chronic treatment with androgens or androgen-estrogen combinations (Bosland 1989; Hoover et al. 1990; Leav et al. 1988, 1989; Noble 1982; Pollard et al. 1982; Pollard and Luckert 1986; Pour and Stepan 1987; Shirai et al. 1991) or by exposure to chemical carcinogens and simultaneous hormonal stimulation of prostatic cell proliferation (Bosland et al. 1983; Bosland and Prinsen 1990; Pour and Stepan 1987; Shirai et al. 1991). Combination of such carcinogen treatment with chronic administration of androgens leads to a high incidence of dorsolateral prostate adenocarcinomas (Bosland 1989; Hoover et al. 1990; Pollard and Luckert 1986; Pour and Stepan 1987; Shirai et al. 1991).

Adenoma

Adenomas occur with variable, but low, incidence in the ventral prostate of many if not all rat strains (Bosland 1987b; Mitsumori and Elwell 1988). Adenomas are rare in the dorsolateral prostate (Bosland 1987b). The morphology of spontaneously occurring and chemically induced adenomas of the *ventral prostate* has been described in detail elsewhere (Bosland 1987b; Isaacs 1984; Reznik 1990; Reznik et al. 1981; Ward et al. 1980). Adenomas can occur multifocally at any location in the ventral prostate lobe, and they have a characteristically cribriform growth pattern with occasionally some comedo, solid, or microglandular-tubular areas (Fig. 6). Focal dysplasia and squamous metaplasia may be present, particularly in larger adenomas (Reznik et al. 1981). As indicated earlier, the process of devel-

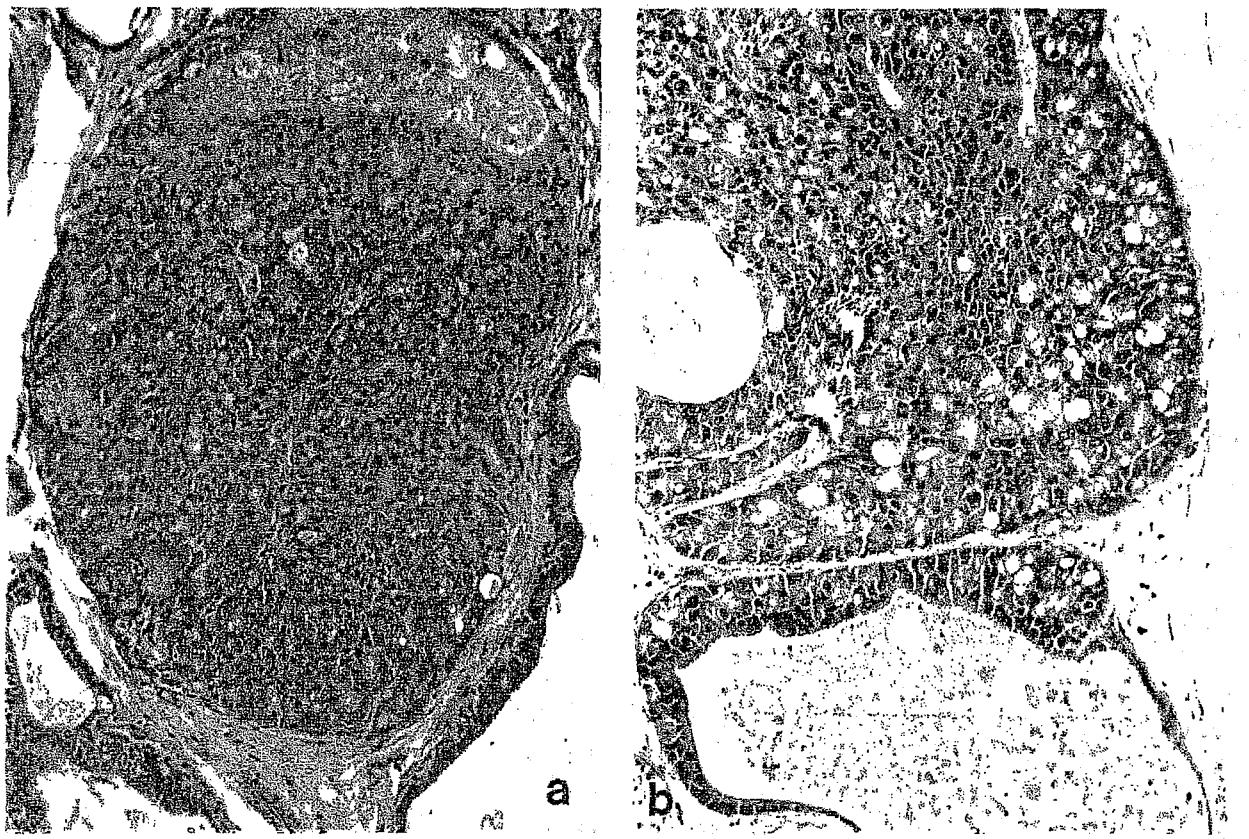

Fig. 6a, b. Adenoma, ventral prostate. **a** Small adenoma that completely obliterates the acinar lumen; there is some capsule formation, but no more than minimal compression of surrounding tissue and no comedo growth pattern. H&E, × 135. **b** Detail of large adenoma. There is a comedo growth pattern and moderate atypia, but hardly any capsule formation and no obvious invasive growth; the lesion is in part sharply demarcated but also merges with normal epithelium in some areas. H&E, × 135

opment of ventral prostate carcinomas is a continuum, and therefore hyperplasia and adenomas have sometimes been classified as carcinomas in situ (Katayama et al. 1982). However, since there is no evidence that all cases of hyperplasia and all adenomas eventually would progress to carcinoma, this term is best avoided. In contrast to atypical hyperplasia, adenomas (almost) completely obliterate the lumen of one to several adjacent alveoli by intra-alveolar epithelial proliferations, distort normal alveolar architecture, and compress surrounding tissue (Table 7). A fine fibrous capsule can surround the lesion. Although there is sometimes outgrowth into adjacent alveolar lumina or ducts, the lesions do not exhibit clear invasive growth, which is a conclusive criterion for separating adenomas from carcinomas that do not metastasize (Table 7). Grading of prostate adenomas can be done according to size.

A single case of cystadenoma of the ventral prostate and a single case of adenoma of the *dorsolateral prostate* have been described in the literature (Bosland 1987b; Bosland and Prinsen 1990). Cribriform adenomas which are morphologically similar to those in the ventral prostate may also occur in the dorsolateral prostate, but these have only been found in carcinogen-treated rats (Bosland, unpublished data).

Adenocarcinoma

Adenocarcinoma of the rat male accessory sex glands is rare as a spontaneous finding. Only ventral prostate adenocarcinomas are found in some rat strains with some regularity. The morphology of adenocarcinomas of the *ventral prostate* has been described in detail elsewhere (Bosland 1987a; Isaacs 1984; Reznik 1990; Reznik et al. 1981; Ward et al. 1980). These tumors are epithelial proliferations that vary in

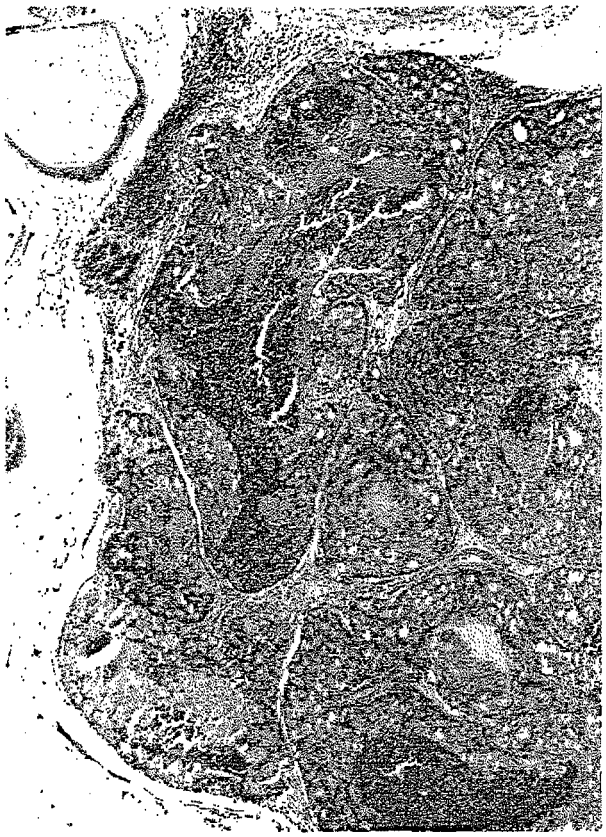

Fig. 7. Large cribriform adenocarcinoma, ventral prostate. There is severe distortion of normal architecture and marked capsule formation, as well as some invasive growth into the capsule and mononuclear inflammatory infiltrate. The lesion has a distinct comedo growth pattern and necrotic areas. H&E, × 55

size from five alveoli to the entire ventral lobe, often grossly distorting its architecture (Fig. 7). A distinct fibrous capsule is often present surrounding the tumor process and sharply demarcating it. Fibrous stromal septa dividing the tumor into pseudolobules are a frequent feature. There may be a mild mixed cell inflammatory infiltrate. Invasive growth is generally limited to invasion of surrounding alveoli and stroma, and perineural invasion and metastases from ventral prostate carcinomas have not been reported (Reznik et al. 1981; Ward et al. 1980), although Isaacs (1984) reported blood vessel infiltration. Cribriform, comedo, and solid growth patterns predominate, and there is a higher degree of cellular atypia than in adenomas and atypical hyperplasias (Ward et al. 1980). Although invasive growth and metastases are conclusive criteria for separating adenomas from carcinomas, since most ventral prostate adenocarcinomas are of low-grade malignancy, distinction between adenoma and carcinoma is often difficult and somewhat arbitrary. Practical criteria for this purpose are size and the presence of distinct cellular and nuclear pleomorphism, comedo growth patterns, and central necrosis (Table 7). It is not conceivable that large tumors, involving more than approximately ten alveoli, have not invaded through alveolar walls, although there may be no histologic evidence for invasive growth other than fibroplasia.

Adenocarcinomas of the *dorsolateral prostate* have been described in detail elsewhere (Bosland 1987a; Bosland et al. 1990; Shirai et al. 1991). These tumors have a glandular growth pattern with an often abundant amount of stromal tissue. Cribriform and comedo growth patterns have not been reported. These carcinomas are always invasive, infiltrating blood vessels and perineural spaces and invading the glandular capsule and surrounding tissues. A marked mixed cell inflammatory infiltrate is common in these tumors. At the time of death of the animal they have generally invaded into several accessory sex gland structures, impeding determination of the exact site of origin. These carcinomas display a considerable variation in degree of differentiation. Anaplastic carcinomas are probably an undifferentiated variety of adenocarcinoma. Adenocarcinomas metastasize, primarily to the regional lymph nodes and lungs, but also to the liver (Bosland et al. 1983; Bosland and Prinsen 1990; Shirai et al. 1991), indicating that both hematogenous and lymphatic dissemination can occur. Skeletal metastases have not been described. Although the histogenesis of these carcinomas has not been thoroughly studied, they seem to arise de novo rather than via a benign stage (Bosland 1987a; Bosland et al. 1990; Shirai et al. 1991).

Grading of prostate carcinomas can best be accomplished on the basis of size and degree of differentiation, whereas for staging purposes metastatic and nonmetastatic carcinomas may be distinguished.

Squamous Cell Carcinoma

There is only one report of a squamous cell carcinoma in the rat prostate (Mitsumori and

Table 8. Incidence (%) of nonneoplastic lesions in the coagulating gland of 4- to 33-month-old Wistar (Cpb:WU) rats[a]

	Age (months)			
	4	13	25	33
No. of animals	49	50	71	44
Inflammation (n.o.s.)	2	0	0	0
Atrophy, diffuse	0	0	6	10
Hyperplasia				
Atypical	0	0	1	0
Seminal vesicle-like	0	0	1	5

[a] M.C. Bosland (unpublished data).

Elwell 1988); this neoplasm occurred in the dorsolateral lobe. Squamous cell carcinomas have been induced in the ventral and dorsolateral prostate by some chemical carcinogens (Pour 1983; Pour and Stepan 1987; Rivenson and Silverman 1979). Keratinization may be present in these tumors.

Coagulating Gland

There are very few reports about spontaneous lesions of the rat coagulating gland. The coagulating gland is often not required to be examined in the routine practice of toxicologic pathology (NTP 1984; OECD 1981; US EPA 1983; US FDA 1982). Thus, there is no information about the incidence of spontaneously occurring lesions in this prostate lobe in aging rats, with the exception of some unpublished data on Cpb:WU rats summarized in Table 8.

Nonneoplastic Lesions

Inflammation

Inflammation is an infrequent lesion in the rat coagulating gland (Table 8). The inflammation is often diffuse rather than focal. It is frequently associated with inflammatory changes in the adjacent seminal vesicle, but there is probably no correlation with inflammatory lesions in other accessory sex glands (M.C. Bosland, unpublished data).

Atrophy

Androgen deprivation-induced, diffuse atrophy is an age-related change that occurs in the Cpb:WU Wistar strain with low frequency in rats of 2 years old and over. The amount of secretion is greatly reduced, there is an apparent loss of epithelial cells, and the amount of fibromuscular stroma seems to be increased. The size and weight of the gland are reduced. Diffuse atrophy of the coagulating gland often occurs bilaterally and in combination with atrophy of the seminal vesicles, but there is probably no association with atrophic changes in other accessory sex glands. A second form of atrophy consists in a marked flattening of the epithelium which usually occurs in combination with an increased amount of secretory material and dilatation of the glandular lumen.

Hyperplasia

Besides reactive hyperplasia, there are two types of nonreactive hyperplastic changes of the rat coagulating gland. *Reactive hyperplasia* is always combined with inflammatory cell infiltrate and consists of a simple thickening of the epithelium into two to six or more cell layers, and sometimes pseudoglandular structures, at times with some cellular atypia.

Atypical hyperplasia of the coagulating gland is rare. This lesion has not been reported to occur spontaneously, but it can result from treatment with carcinogens (Hoover et al. 1990; Shirai et al. 1991). One such lesion was found in an untreated, 25-month-old Wistar rat (Table 8; M.C. Bosland, unpublished data). It usually occurs in areas with increased glandular infolding, and consists of cells that have lost normal polarity, are slightly enlarged, and have a hypochromatic cytoplasm; the nuclei are usually hypobaso-

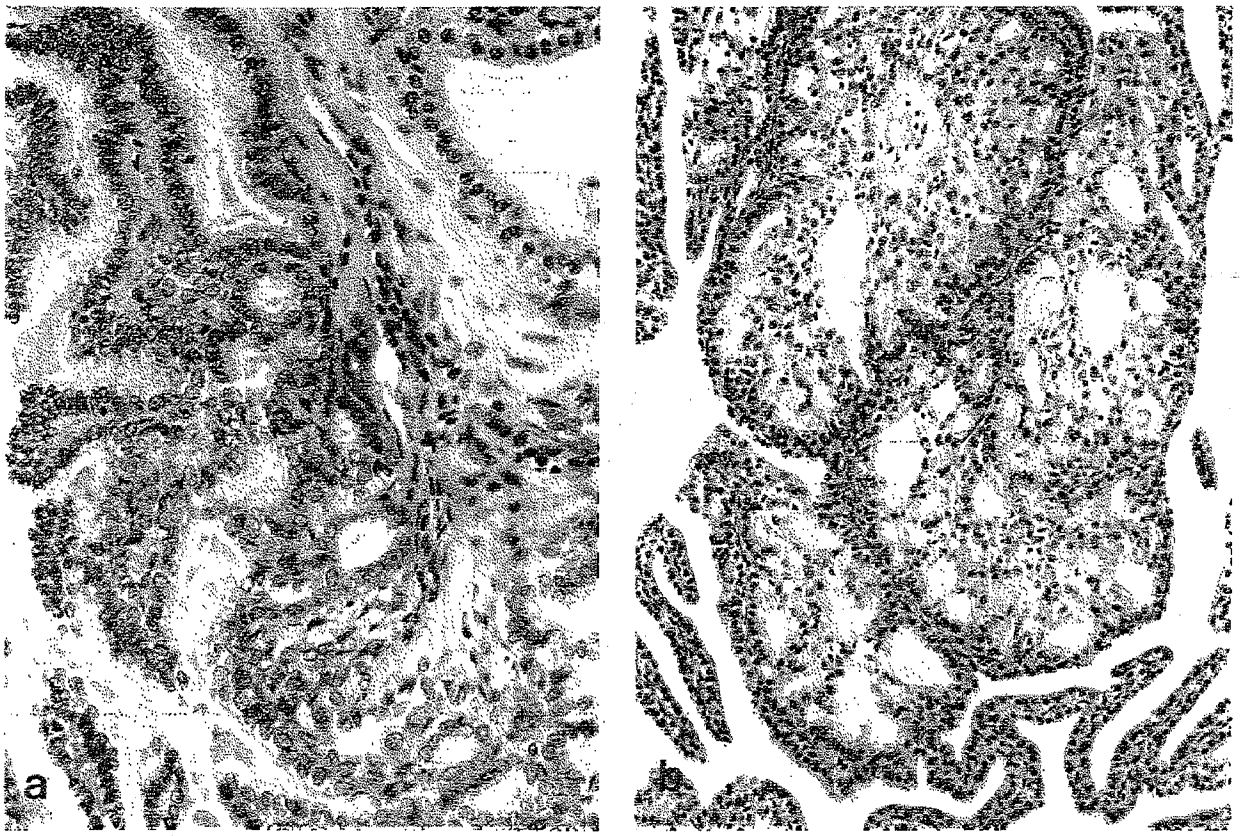

Fig. 8a, b. Atypical hyperplasia, coagulating gland. **a** Proliferation of atypical cells growing in a microglandular fashion. There is some normal epithelium at the *upper right-hand corner*. H&E, × 275. **b** Large area with atypical hyperplasia with a cribriform growth pattern. This lesion is borderline between atypical hyperplasia and adenoma; there is no capsule or clear-cut compression of surrounding tissue, but there is mild distortion of normal architecture. H&E, × 135

philic, but occasionally hyperbasophilic (Fig. 8). The cells are often not piled up and follow the lining of the glandular infolds, but cribriform papillary hyperplasia not unlike that found in the ventral prostate can also occur (M.C. Bosland, unpublished data; Hoover et al. 1990).

Seminal vesicle-like hyperplasia is characterized by the replacement of the normal epithelium of the coagulating gland by epithelial cells that closely resemble or are indistinguishable from seminal vesicle epithelium. The cells in this lesion are thus cylindrical with somewhat elongated, strongly basophilic, basal nuclei (Fig. 9). The number of cells per unit basement membrane is distinctly increased in comparison with normal epithelium, and the amount of glandular infolding is usually also increased. Atypical hyperplasia may occur in this lesion and may be continuous with early-stage adenocarcinoma. This lesion is age-related, but very uncommon, at least in Wistar rats (Table 8). It can occur more frequently in rats treated with carcinogens and/or hormones (Bosland, unpublished data).

Other Nonneoplastic Lesions

Focal *squamous metaplasia*, occasionally with keratinization, can occur in the coagulating gland of aging rats, often as a reaction to inflammation. Diffuse squamous metaplasia has not been reported to occur spontaneously. Squamous metaplasia has been induced by estrogen in the rat seminal vesicle and dorsolateral prostate ducts, but not the ventral prostate or coagulating gland (Ber and Levy 1952). However, the metaplasia-inducing effect of estrogen may be dependent on dose and strain of rat, because it can occur exclusively in the coagulating gland of Wistar rats (M.C. Bosland, unpublished data), as described for the mouse (Bern 1951).

Other nonneoplastic lesions that may occur in the coagulating gland of aging rats include fibrosis, edema, hemorrhage, epithelial degeneration,

Fig. 9. Seminal vesicle-like hyperplasia, coagulating gland (*C*). At the *top*, the lesion merges with normal coagulating gland epithelium. There is also a fragment of normal seminal vesicle (*S*). H&E, × 135

Fig. 10. Atypical hyperplasia, seminal vesicle. This sharply demarcated lesion has a moderate degree of atypia. There is some normal epithelium at the *lower left-hand corner*. H&E, × 135

epithelial vacuolation, mucoid metaplasia, and glandular dilatation.

Neoplastic Lesions

Spontaneously occurring neoplasms of the coagulating gland in aging rats have not been reported in the literature. Adenomas, adenocarcinomas, and squamous papillomas have been observed in rats treated with carcinogens and/or hormones (Bosland 1987a, b; Bosland and Prinsen 1990; Shirai et al. 1991).

Adenoma

Induced adenomas of the coagulating gland are cribriform lesions morphologically similar to those occurring in the ventral prostate (M.C. Bosland, unpublished data). These adenomas are not seen grossly. Demarcation, compression of surrounding tissue, disruption of normal glandular architecture, and cellular atypia within the lesion can be used as criteria to distinguish between adenoma and hyperplasia.

Adenocarcinoma

Induced adenocarcinomas of the coagulating gland have a glandular growth pattern with an abundant stromal tissue (M.C. Bosland, unpublished data; Shirai et al. 1991). Cribriform and comedo growth patterns, similar to those occurring in the ventral prostate, can also occur in the coagulating gland, but are extremely rare (M.C. Bosland, unpublished data). The glandular pattern tumors probably develop de novo and invade the glandular capsule and surrounding tissues, rather than the glandular lumen. When they are larger and have invaded other accessory sex gland structures at the time of death it may be difficult or impossible to determine the exact site of origin. These adenocarcinomas vary considerably in degree of differentiation from very well differentiated to poorly or anaplastic, and they can metastasize.

Table 9. Incidence (%) of nonneoplastic and neoplastic lesions in the seminal vesicle of 25- to 26-month-old F344 rats[a]

	Reference			
	NTP Reports[b]	Goodman[c]	Charles River[d]	Solleveld[e]
No. of animals	808	1754	938	2320
Inflammation (n.o.s.)	2.4 (0–24)	0		
Atrophy (n.o.s.)	11 (0–54)	1.7		
Hyperplasia (n.o.s.)	0.8 (0–13)	0		
Adenoma	0	0	0	0.04
Carcinosarcoma	0	0	0	0.04

[a] This table does not include a study of 296 27- to 30-month-old F344/DuCrj rats that did not have any seminal vesicle neoplasms (Maekawa et al. 1983).
[b] Data for control F344/N rats from 21 NTP carcinogenicity studies (1989 Technical Report Nos. 345, 356–367, 369, 370; 1990 Technical Report Nos. 372–376, 378, 379); range is given in parentheses.
[c] Data on unspecified substrain reported by Goodman et al. (1979).
[d] Control tumor data for CDF (F344/Crl) rats from 13 studies (Charles River Laboratories 1990); range is given in parentheses.
[e] Control tumor data for F344/N rats (Solleveld et al. 1984); this study also included 529 F344/N rats kept for life, none of which (0.2%) developed a seminal vesicle adenocarcinoma.

Table 10. Incidence (%) of nonneoplastic and neoplastic lesions in the seminal vesicle of 1.5- to 46-month-old Sprague-Dawley rats

	Age period (months)				
	1.5–4.5	4.6–7.5	7.6–13.5	13.6–46	25
No. of animals	109[a]	133[a]	81[a]	122[a]	869[b]
Inflammation (n.o.s.)	2	1	1	7	
Atrophy (n.o.s.)	2	15	3	16	
Hyperplasia (n.o.s.)	0	0	0	2	
Hypertrophy (n.o.s.)	0	0	0	3	
(Adeno)carcinoma	0	0	0	0.8	0.5 (0–1.4)
Sarcoma (n.o.s.)	0	0	0	0.8	0

[a] Unpublished data for control Crl:CD(SD) rats from Merck, Sharp and Dohme Research Laboratories, West Point, PA, 1969–1988.
[b] Tumor data for control Crl:CD rats from 13 studies (Charles River Laboratories 1987); range is given in parentheses.

Squamous Papilloma

Squamous papillomas can occur in the ducts of the coagulating gland, but even in carcinogen-treated rats they are extremely rare. Some keratinization may be present. Spontaneous or induced squamous cell carcinomas have never been reported in the rat coagulating gland.

Seminal Vesicle

There is much less information on lesions of the rat seminal vesicle than on those of the prostate. Nevertheless, it is clear that spontaneous lesions of the seminal vesicle are considerably less frequent than those of the prostate. Spontaneous incidences of nonneoplastic and neoplastic seminal vesicle lesions are summarized in Tables 9–11 for F344, Sprague-Dawley, and Wistar rats.

Nonneoplastic Lesions

Inflammation

Inflammation is infrequent in the seminal vesicle of the aging rat (Tables 9–11). As in the coagulating gland, it is often diffuse rather than focal, and frequently associated with inflammation in

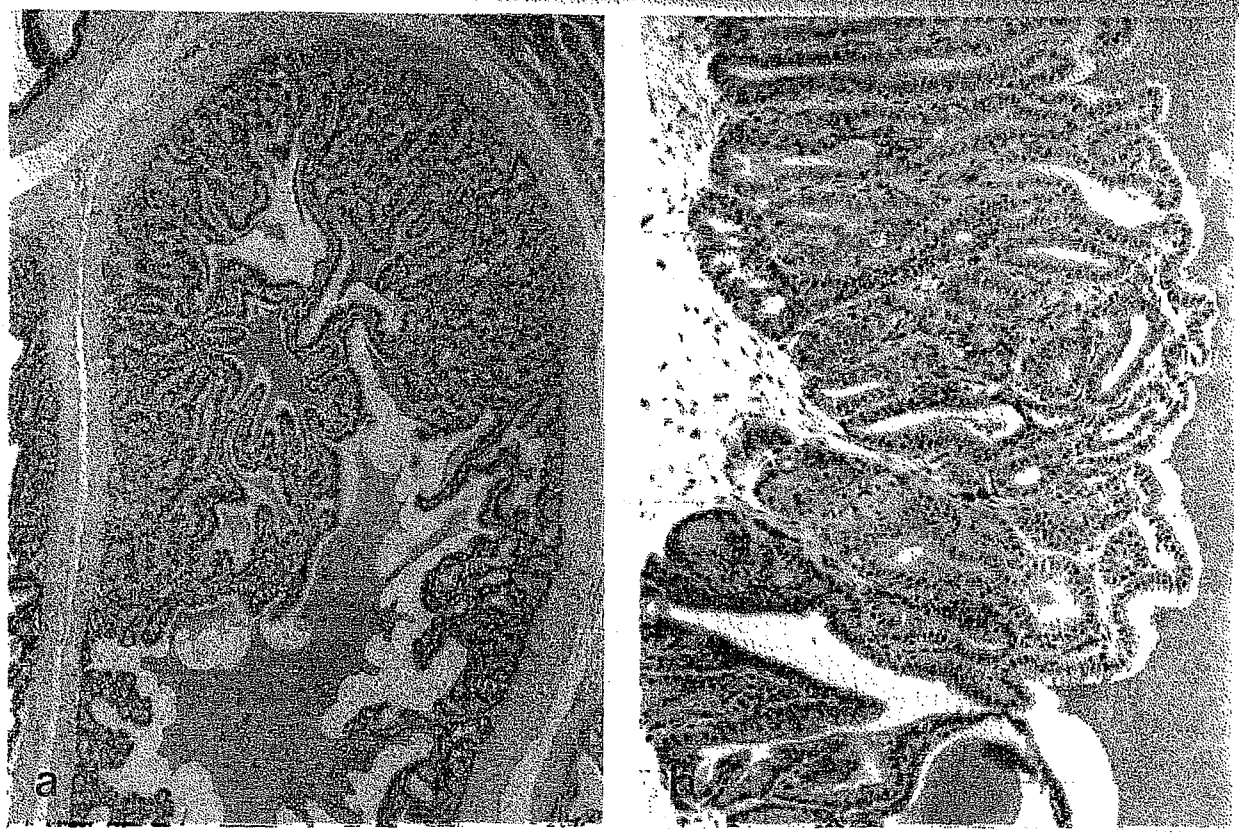

Fig. 11a, b. Combination of hyperplasia and cellular hypertrophy, seminal vesicle. **a** Large lesion that abruptly merges with normal epithelium at the *lower right-hand side.* H&E, × 55. **b** Small lesion that abruptly merges with normal epithelium at the *bottom.* H&E, × 135

the adjacent coagulating gland. It may occur bilaterally. There is no established correlation with inflammation in other accessory sex glands (M.C. Bosland, unpublished data).

The low incidences of inflammatory lesions of the seminal vesicle in F344 and Wistar rats presented in Tables 9 and 11 are in good agreement with those reported for F344 rats by Anver et al. (1982) and those observed in the Cpb:WU Wistar substrain (M.C. Bosland, unpublished data).

Atrophy

There are two types of atrophy in the rat seminal vesicle. Diffuse atrophy resulting from androgen deprivation is characterized by a decreased amount of secretory material, a loss of epithelial cells, an apparent increase in fibromuscular stroma, and a reduction in the size and weight of the gland. This type of atrophy often occurs bilaterally and in combination with atrophy of the coagulating gland, but probably not in association with atrophy of other accessory sex glands. The second type of atrophy is a flattening of the epithelium which occurs in combination with an increased amount of secretory material and dilatation of the glandular lumen.

The spontaneous incidence of atrophy of the seminal vesicle is not high in F344, Sprague-Dawley, and Wistar rats, but in most studies it increases somewhat with aging (Tables 9–11). The low incidences for F344 rats in Table 9 are in contrast with data from Anver et al. (1982) indicating a 48%–67% incidence in 18- to 33-month-old F344 rats. It is not clear what factors are responsible for this variability among these studies. Incidence data for the Cpb:WU rat (Table 12), on the other hand, are in good agreement with those for another Wistar substrain presented in Table 11.

Hyperplasia

Besides reactive hyperplasia, there are basically two types of nonreactive hyperplastic lesions of

Table 11. Incidence (%) of nonneoplastic and neoplastic lesions in the seminal vesicle of 24- to 30-month-old Wistar (Hoe:Wiskf/SPF71) rats[a]

	Age period (months)	
	24–26 (10 studies)	27–30 (12 studies)
No. of animals	522	790
Inflammation (n.o.s.)	3 (2–4)[b]	3 (3–4)
Atrophy/hyposecretion	5 (3–6)	13 (3–26)
Dilatation	3 (1–5)	0
Hyperplasia (n.o.s.)	0.4 (0–4)	0
Carcinoma	0	0.25
Carcinosarcoma	0	0.13

[a] Data for control rats from Hoechst AG, Frankfurt, Germany, 1982–1990.
[b] Range is given in parentheses.

Table 12. Incidence (%) of nonneoplastic and neoplastic lesions in the seminal vesicle of 4- to 33-month-old Wistar (Cpb:WU) rats[a]

	Age (months)				
	4	13	25	33	25–33
No. of animals	49	50	71	33	3861[b]
Atrophy, diffuse	0	0	6	9	
Hyperplasia + hypertrophy	0	0	3	2	
Adenocarcinoma					0.03[c]

[a] M.C. Bosland, unpublished data for control Cpb:WU rats.
[b] Number of Cpb:WU rats for which tumor data were available (TNO-CIVO Toxicology & Nutrition Institute, Zeist, The Netherlands, 1976–1987).
[c] Originated from dorsolateral lobe.

the rat seminal vesicle. *Reactive hyperplasia* is always combined with inflammatory cell infiltrate and often consists of a thickening of the epithelium with or without pseudoglandular structures. The hyperplastic cells are often slightly atypical.

Atypical hyperplasia of the seminal vesicle (Fig. 10) consists of pale cells that have lost normal cellular polarity and display moderate nuclear and cellular atypia and distinct pleomorphism (Bosland and Prinsen 1990). The cells are disarranged and often piled-up in solid, microgland, and/or cribriform patterns. Compression of surrounding tissue can occur.

Another spontaneous focal lesion in the seminal vesicle is a combination of cellular *hyperplasia* and *hypertrophy* (Fig. 11), described in detail elsewhere (Bosland 1987d; Bosland and Prinsen 1990; Shirai et al. 1987). This lesion was found in 2%–3% of 104 Cpb:WU rats of 25–33 months of age (Table 12) (M.C. Bosland, unpublished data). The cellular hypertrophy is often more prominent than the hyperplasia, particularly in small lesions. In contrast to atypical hyperplasia, there is at most slight cellular atypia but no pleomorphism, and the cells follow the normal glandular contours. The lesion is well demarcated, with abrupt transitions from normal epithelium to the affected epithelium. Very large lesions can compress surrounding epithelium. This lesion sometimes contains areas of atypical hyperplasia but it has never been associated with carcinoma (Bosland 1987d; Bosland and Prinsen 1990). A similar lesion has not been described in the other accessory sex gland structures.

Both types of hyperplastic lesions can result from treatment with carcinogens (Bosland 1987d; Bosland and Prinsen 1990; Shirai et al. 1987).

The type of hyperplasia (or hypertrophy) in Tables 9–11 was not determined, but it is evident that hyperplastic lesions are rare in the seminal vesicle of aging rats.

Other Nonneoplastic Lesions

Focal *squamous metaplasia* can occur in aging rats as a reaction to the presence of inflammation in the seminal vesicle. Spontaneous, diffuse squamous metaplasia has not been reported, but it may be induced by estrogen in the rat seminal vesicle (Ber and Levy 1952). Dilatation, as a result of either apparent hypersecretion or obstruction of the seminal vesicle duct, is very rare (Table 11). Other nonneoplastic lesions that can occur are similar to those listed for the coagulating gland.

Neoplastic Lesions

Adenoma

There is one report that describes the morphology of a spontaneous seminal vesicle adenoma (Boorman et al. 1990). This lesion compressed surrounding tissue. It consisted of epithelium arranged in a papillary and glandular pattern. There was some nuclear atypia and cellular crowding, but the cells otherwise closely resembled normal epithelium. Demarcation, compression of surrounding tissue, disruption of normal glandular architecture, and cellular atypia within the lesion may serve as criteria to distinguish adenoma from hyperplasia. Seminal vesicle adenoma has been reported with a very low incidence in F344 rats (Table 9) but not in other strains.

Adenocarcinoma

Adenocarcinomas of the seminal vesicle usually have a glandular growth pattern with an abundant amount of stromal tissue (M.C. Bosland, unpublished data; Bosland 1987d; Hoover et al. 1990; Shirai et al. 1991). The carcinomas invade the glandular capsule and surrounding tissues, but not the glandular lumen. Large carcinomas of the seminal vesicle and coagulating gland often cannot be distinguished. Seminal vesicle adenocarcinomas vary considerably in degree of differentiation. They can metastasize. The spontaneous incidence of these carcinomas is low to very low; they are somewhat more frequent in Sprague-Dawley rats than in F344 or Wistar rats (Tables 9–11). In the Cpb:WU Wistar substrain they are less frequent (0.03%; n = 3861; M.C. Bosland, unpublished data) than in the Hoe: Wiskf/SPF71 rats (Table 11). Seminal vesicle adenocarcinomas can be induced with carcinogens and hormones (Bosland and Prinsen 1990; Hoover et al. 1990; Shirai et al. 1991).

Squamous Papilloma

Squamous papillomas can occur in the ducts of the seminal vesicle of carcinogen-treated rats, but are rare. Keratinization may be present. Spontaneous or induced squamous cell carcinomas have never been reported in the rat seminal vesicle.

Ampullary Gland

Very little is known about spontaneous or induced lesions in the rat ampullary gland. *Chronic inflammation* and *reactive hyperplasia* are the only lesions that probably occur with a significant incidence. They probably result from sperm reflux and can ultimately develop into *sperm granulomas* (Bosland and Prinsen 1990; Mesfin et al. 1989). Such reactive lesions occur in Cpb:WU rats of all (adult) ages, and they are more frequent (approx. 25%) in young adult rats (4 months old) than in 1- to 2-year-old rats (5%–15%; M.C. Bosland, unpublished data). Focal sclerotic atrophy also occurs more often in young than in old rats of this strain, and this lesion may represent a late stage of the chronic inflammatory lesion. Acute inflammation is rare. Besides reactive hyperplasia, *atypical hyperplasia* may occur in the ampullary gland, but this lesion has only been found in carcinogen-treated rats (Bosland MC, unpublished data). Such atypical hyperplasia of the ampullary gland consists in proliferation of cells which are, in comparison with normal epithelium, somewhat enlarged and have a pale cytoplasm and nuclei. Some of the hyperplastic cells may be similar to normal ampullary epithelium. The epithelium is thickened in as many as seven cell layers and intraepithelial microglandular formations are frequent.

Spontaneously occurring *neoplastic lesions* of the ampullary gland have not been described, nor

have they ever been observed in carcinogen-treated rats.

Bulbourethral Gland

There are no reports of spontaneous or induced nonneoplastic or neoplastic lesions of the rat bulbourethral gland.

Mesenchymal Accessory Sex Gland Tumors

A variety of spontaneous and chemically induced mesenchymal tumors can occur in the rat accessory sex glands: leiomyosarcoma, fibroma, fibrosarcoma, paraganglioma, neurofibroma, neurofibrosarcoma, histiocytic sarcoma, hibernoma, mesothelioma, undifferentiated sarcoma, and metastases such as from generalized lymphomas (M.C. Bosland, unpublished data; Bosland and Prinsen 1990; Goodman et al. 1980; Solleveld et al. 1984). Their morphology does not differ from similar tumors found elsewhere.

Urethra and Prostatic Utricle

There are no reports of spontaneous or induced nonneoplastic lesions of the rat urethra. There is one report of a spontaneous transitional cell carcinoma of the prostatic urethra in an aged F344 rat (Mitsumori and Elwell 1988). Urethral squamous papillomas and squamous cell carcinomas have been observed in carcinogen-treated rats (M.C. Bosland, unpublished data; Pour and Stepan 1987; Pour et al. 1979).

Penis and Prepuce

Nonneoplastic and neoplastic lesions of the penis and prepuce are very rare in rats. Kroes et al. (1981) described a 1.2% incidence of necrotizing inflammation of the penis in 170 aged Wistar SPF Tox rats, but no such lesions in 174 aged rats of the closely related Cpb:WU Wistar substrain. A rare squamous papilloma and squamous cell carcinoma of the penis and a few keratoacanthomas and squamous cell carcinomas of the prepuce have been reported in aged F344 rats (Mitsumori and Elwell 1988).

Acknowledgments

This work was supported in part by Grant No. CIVO 84-3 from the Dutch Cancer Foundation, Grants No. CA43151, CA48084, and CA13343 from the National Cancer Institute, Grant No. ES00260 from the National Institute of Environmental Health Sciences, and Grant No. CR813481 from the Environmental Protection Agency.

References

Anver MR, Cohen BJ, Lattuada CP, Foster SJ (1982) Age-associated lesions in barrier-reared male Sprague-Dawley rats: a comparison between Hap:(SD) and Crl:COBS® CD® (SD) stocks. Exp Aging Res 8:3–24

Aronsson A, Dahlgren S, Gatenbeck L, Strömberg L (1988) Predictive sites of inflammation in the prostatic gland: an experimental study on nonbacterial prostatitis in the rat. Prostate 13:17–25

Aumüller G, Enderle-Schmidt U, Seitz J, Müntzing J, Chandler JA (1987) Ultrastructure and immunohistochemistry of the lateral prostate in aged rats. Prostate 10:245–256

Ber HA, Levy RS (1952) The effects of castration, estrogen administration, and methylcholanthrene carcinogenesis on phosphatase activity in the genital tract of male rats, guinea pigs, and rabbits. Am J Anat 90:131–165

Bern HA (1951) Estrogen and alkaline phosphatase activity in the genital tract of the male mouse. Endocrinology 48:25–33

Boorman GA (1985) Bronchiolar/alveolar adenoma, lung, rat. In: Jones TC, Mohr U, Hunt RD (eds) Respiratory system. Springer, Berlin Heidelberg New York, pp 99–101 (Monographs on pathology of laboratory animals)

Boorman GA, Eustis SL, Mitsumori K (1990) Neoplasms of the seminal vesicle. In: Stinson SF, Schüller HM, Reznik G (eds) Atlas of tumor pathology of the Fischer rat. CRC Press, Boca Raton, pp 415–418

Bosland MC (1987a) Adenocarcinoma, prostate, rat. In: Jones TC, Mohr U, Hunt RD (eds) Genital system. Springer, Berlin Heidelberg New York, pp 252–260 (Monographs on pathology of laboratory animals)

Bosland MC (1987b) Adenoma, prostate, rat. In: Jones TC, Mohr U, Hunt RD (eds) Genital system. Springer, Berlin Heidelberg New York, pp 261–266 (Monographs on pathology of laboratory animals)

Bosland MC (1987c) Hyperplasia, prostate, rat. In: Jones TC, Mohr U, Hunt RD (eds) Genital system. Springer, Berlin Heidelberg New York, pp 267–272 (Monographs on pathology of laboratory animals)

Bosland MC (1987d) Adenocarcinoma, seminal vesicle/

coagulating gland, rat. In: Jones TC, Mohr U, Hunt RD (eds) Genital system. Springer, Berlin Heidelberg New York, pp 272–275 (Monographs on pathology of laboratory animals)

Bosland MC (1989) Promotion by testosterone of *N*-methyl-*N*-nitrosourea-induced prostatic carcinogenesis in rats. Proc Am Assoc Cancer Res 30:272

Bosland MC, Prinsen MK, Kroes R (1983) Adenocarcinomas of the prostate induced by *N*-nitroso-*N*-methylurea in rats pretreated with cyproterone acetate and testosterone. Cancer Lett 18:69–78

Bosland MC, Prinsen MK, Dirksen TJM, Spit BJ (1990) Characterization of adenocarcinomas of the dorsolateral prostate induced in Wistar rats by *N*-methyl-*N*-nitrosourea, 7,12-dimethylbenz[a]anthracene, and 3,2'-dimethyl-4-aminobiphenyl following sequential treatment with cyproterone acetate and testosterone propionate. Cancer Res 50:700–709

Burek JD (1978) Pathology of aging rats. CRC Press, Boca Raton

Charles River Laboratories (1987) Spontaneous neoplastic lesions in the Crl:CDBR rat. Charles River Laboratories, Wilmington

Charles River Laboratories (1990) Spontaneous neoplastic lesions in the CDF[F344]/CrlBR rat. Charles River Laboratories, Wilmington

Coleman GL, Barthold W, Osbaldiston GW, Foster SJ, Jonas AM (1977) Pathological changes during aging in barrier-reared Fischer F344 male rats. J Gerontol 32:258–278

Friedlander AM, Braude AI (1972) Experimental prostatitis: relationship to pyelonephritis. J Infect Dis 126:645–651

Gatenbeck L, Aronsson A, Dahlgren S, Johansson B, Strömberg L (1987) Stress-induced histopathological changes in the prostate: an experimental study in the rat. Prostate 11:69–76

Goodman DG, Ward JM, Squire RA, Chu KC, Linhart MS (1979) Neoplastic and nonneoplastic lesions in aging F344 rats. Toxicol Appl Pharmacol 48:237–248

Goodman DG, Ward JM, Squire RA, Paxton MB, Reichardt WD, Chu KC, Linhart MS (1980) Neoplastic and nonneoplastic lesions in aging Osborne-Mendel rats. Toxicol Appl Pharmacol 55:433–447

Hoover DM, Best KL, McKenney BK, Tamura RN, Neubauer BL (1990) Experimental induction of neoplasia in the accessory sex organs of male Lobund-Wistar rats. Cancer Res 50:142–146

Isaacs JT (1984) The aging ACI/Seg versus Copenhagen male rat as a model for the study of prostatic carcinogenesis. Cancer Res 44:5785–5796

Jesik CJ, Holland JM, Lee C (1982) An anatomic and histologic study of the rat prostate. Prostate 3:81–97

Kaplan L, Lee C, Schaeffer AJ (1983) Effect of castration on experimental bacterial prostatitis in the rat. Prostate 4:625–630

Katayama S, Fiala E, Reddy BS, Rivenson A, Silverman J, Williams GM, Weisburger JH (1982) Prostate adenocarcinomas in rats, induction by 3,2'-dimethyl-4-aminobiphenyl. J Natl Cancer Inst 68:867–873

Kerr JFR, Searle J (1973) Deletion of cells by apoptosis during castration-induced involution of the rat prostate. Virchows Arch [B] 13:87–102

Kroes R, Garbis-Berkvens JM, de Vries T, van Nesselrooij JHJ (1981) Histopathological profile of a Wistar rat stock including a survey of the literature. J Gerontol 36:259–279

Leav I, Ho S-M, Ofner P, Merk FB, Kwan PW-L, Damassa D (1988) Biochemical alterations in sex hormone-induced hyperplasia and dysplasia of the dorsolateral prostates of Noble rats. J Natl Cancer Inst 80:1045–1050

Leav I, Merk FB, Kwan PW-L, Ho S-M (1989) Androgen-supported estrogen-enhanced epithelial proliferation in the prostates of intact Noble rats. Prostate 15:3–40

Lee C, Grayhack JT (1989) Prolactin and prostate in animal models. In: Nagasawa H (ed) Prolactin and lesions in breast, uterus, and prostate. CRC Press, Boca Raton, pp 177–186

Lee C, Holland JM (1987) Anatomy, histology, and ultrastructure (correlation with function), prostate, rat. In: Jones TC, Mohr U, Hunt RD (eds) Genital system. Springer, Berlin Heidelberg New York, pp 239–251 (Monographs on pathology of laboratory animals)

Levy BJ, Fair WR (1973) The location of antibacterial activity in the rat prostatic secretions. Invest Urol 11:173–177

Lundgren R, Holmquist B, Hesselvik M, Müntzing J (1984) Treatment of prostatitis in the rat. Prostate 5:277–284

Maekawa A, Kurokawa Y, Takahashi M, Kokubo T, Ogiu T, Onodera H, Toshaiki O, Tagawa H, Ohno Y, Furakawa F, Hayashi Y (1983) Spontaneous tumors in F-344/DuCjr rats. Gann 74:365–372

Merk F, Warhol MJ, Kwan PW-L, Leav I, Alroy J, Ofner P, Pinkus GS (1986) Multiple phenotypes of prostatic glandular cells in castrated dogs after individual or combined treatment with androgen and estrogen. Morphometric, ultrastructural and cytochemical distinctions. Lab Invest 54:442–456

Mesfin GM, Factor SS, Higgins MJ (1989) Pathological changes in the accessory sex glands of rats treated with a sympatholytic hypotensive agent (Losulazine). Toxicol Pathol 17:516–524

Mitsumori K, Elwell MR (1988) Proliferative lesions in the male reproductive systems of F344 rats and B6C3F1 mice: incidence and classification. Environ Health Perspect 77:11–21

Müntzing J, Sufrin G, Murphy GP (1979) Prostatitis in the rat. Scan J Urol Nephrol 13:17–22

Noble RL (1982) Prostate carcinoma of the Nb rat in relation to hormones. Int Rev Exp Pathol 23:113–159

NTP (1984) National Toxicology Program general statement of work for the conduct of acute, fourteen day repeated dose, 90-day subchronic, and 2-year chronic studies in rodents. National Toxicology Program, National Institute of Environmental Health Sciences, Research Triangle Park

OECD (1981) OECD guidelines for testing of chemicals. Organization for Economic Cooperation and Development, Paris

Pollard MP, Luckert PH (1986) Production of autochthonous prostate cancer in Lobund-Wistar rats by treatments with *N*-methyl-*N*-nitrosourea and testosterone. J Natl Cancer Inst 32:583–587

Pollard MP, Luckert PH, Schmidt MA (1982) Induction of prostate adenocarcinomas in Lobund-Wistar rats by testosterone. Prostate 3:563–568

Pour PM (1983) Prostatic cancer induced in MRC rats by *N*-nitrosobis(2-oxopropyl)amine and *N*-nitrosobis(2-hydroxypropyl)amine. Carcinogenesis 4:49–55

Pour PM, Salamasi S, Runge R, Gingell R, Wallcave L, Nagel D, Stepan K (1979) Carcinogenicity of *N*-nitrosobis(2-oxopropyl)amine in MRC rats. J Natl Cancer Inst 63:181–190

Pour PM, Stepan K (1987) Induction of prostatic carcinomas and lower urinary tract neoplasms by combined treatment of intact and castrated rats with testosterone propionate and *N*-nitrosobis(2-oxopropyl) amine. Cancer Res 47:5699–5706

Price D (1963) Comparative aspects of development and structure in the prostate. Natl Cancer Inst Monogr 12:1–27

Reznik GK (1990) Prostatic hyperplasia and neoplasia. In: Stinson SF, Schüller HM, Reznik G (eds) Atlas of tumor pathology of the Fischer rat. CRC Press, Boca Raton, pp 419–429

Reznik G, Hamlin MH, Ward JM, Stinson SF (1981) Prostatic hyperplasia and neoplasia in aging F344 rats. Prostate 2:261–268

Rivenson A, Silverman J (1979) The prostatic carcinoma in laboratory animals. Invest Urol 16:468–472

Robinette CL (1988) Sex-hormone-induced inflammation and fibromuscular proliferation in the rat lateral prostate. Prostate 12:271–286

Shirai T, Fukushima S, Ikawa E, Tagawa Y, Ito N (1986) Induction of prostate carcinoma in situ at high incidence in F344 rats by a combination of 3,2'-dimethyl-4-aminobiphenyl and ethinyl estradiol. Cancer Res 46:6423–6426

Shirai T, Ikawa E, Tagawa Y, Ito N (1987) Lesions of the prostate glands and seminal vesicles induced by *N*-methyl-*N*-nitrosourea in F344 rats pretreated with ethinyl estradiol. Cancer Lett 35:7–15

Shirai T, Tamano S, Kato T, Iwasaki S, Takahashi S, Ito N (1991) Induction of invasive carcinomas in the accessory sex organs other than the ventral prostate of rats given 3,2'-dimethyl-4-aminobiphenyl and testosterone propionate. Cancer Res 51:1264–1269

Solleveld HA, Haseman JK, McConnell EE (1984) Natural history of body weight gain, survival, and neoplasia in the F344 rat. J Natl Cancer Inst 72:929–940

Stiens R, Helpap B (1981a) Histologische und proliferationskinetische Untersuchungen zum Wachstum der Ratteprostata in verschiedenen Lebensaltern. Acta Anat 109:79–88

Stiens R, Helpap B (1981b) Experimentelle Untersuchungen zum Zellverlust und zur Zellneubildung der Ratteprostata nach Kastration und Androgenzufuhr. Urol Int 36:88–99

Thiedemann K-U (1987) Fetal development of male and female genital tract, mouse. In: Jones TC, Mohr U, Hunt RD (eds) Genital system. Springer, Berlin Heidelberg New York, pp 55–69 (Monographs on pathology of laboratory animals)

US EPA (1983) Good laboratory practice standards: toxicology testing. Fed Regist 48:539222

US FDA (1982) Toxicological principles for the safety assessment of direct food additives and color additives used in food. US Food and Drug Agency, National Information Service, Washington, pp 80–107

Waalkes MP, Rehm S, Riggs CW, Bare RM, Devor DE, Poirier LA, Wenk ML, Hennemann JR, Balaschak MS (1988) Cadmium carcinogenesis in male Wistar [Crl:(WI)BR] rats: dose-response analysis of tumor induction in the prostate and testes and at the site of injection. Cancer Res 48:4656–4663

Waalkes MP, Rehm S, Riggs CW, Bare RM, Devor DE, Poirier LA, Wenk ML, Hennemann JR (1989) Cadmium carcinogenesis in male Wistar[Crl:(WI)BR] rats: dose-response analysis of effects of zinc on tumor induction in the prostate, in the testes, and at the site of injection. Cancer Res 49:4282–4288

Ward JM, Reznik G, Stinson SF, Lattirada CP, Longfellow DG, Cameron TP (1980) Histogenesis and morphology of naturally occurring prostatic carcinoma in the ACI/segHapBR rat. Lab Invest 43:517–522

Bosland MC, Tuomari DL, Elwell MR, Shirai T, Ward JM, and McConnell RF (1998). Proliferative lesions of the prostate and other accessory sex glands in male rats, URG-4. In: Guides for Toxicologic Pathology, STP/ARP/AFIP. Washington, DC.

Proliferative Lesions of the Prostate and Other Accessory Sex Glands in Male Rats

M. C. Bosland,[1] D. L. Tuomari,[2] M. R. Elwell,[3] T. Shirai,[4] J. M. Ward,[5] and R. F. McConnell[6]

[1]NYU Medical Center, New York, NY
[2]Schering-Plough Research Institute, Lafayette, NJ
[3]Experimental Pathology Laboratories, Inc., Herndon, VA
[4]Nagoya City University Medical School, Nagoya, Japan
[5]National Cancer Institute, Frederick, MD
[6]Consultant Pathology Services, Flemington, NJ

INTRODUCTION

Spontaneously occurring proliferative lesions of the accessory sex glands of the male rat are infrequent, with the exception of atypical hyperplasia of the ventral prostate which has a variable incidence in many rat strains. Most macroscopic changes that could be indicative of a tumor, such as diffuse or nodular enlargements, are more likely to represent inflammation rather than proliferative lesions. Accessory sex gland tumors may be microscopic or grossly visible, sometimes they can be so large that it is difficult to determine from which accessory sex gland they originate. The main accessory sex glands in the male rat have intricate structural relationships and consist of the multilobulated prostate (including the coagulating glands), ampullary glands, and seminal vesicles (23). Other accessory sex glands, such as the bulbourethral gland and periurethral glands, are usually not examined routinely in toxicity or carcinogenicity studies and are not discussed here. The preputial glands are not accessory sex glands in a strict sense; proliferative lesions in these glands are discussed elsewhere (19, 32).

Address correspondence to: Society of Toxicologic Pathologists, 19 Mantua Road, Mt. Royal NJ 08061

Detection of male accessory sex gland lesions is subject to several sources of potential bias. First, tissue sampling and processing may introduce inaccuracy and variation. Second, the anatomical complexity of the accessory sex glands discourages a uniform histopathological evaluation and may thereby introduce inter- and intra-observer bias. To reduce both types of bias, anatomical considerations and recommendations for standardizing sampling methods and examination of the male rat accessory sex glands are discussed first.

ANATOMICAL CONSIDERATIONS AND METHODS OF EXAMINATION

ANATOMICAL CONSIDERATIONS

The nomenclature presented here is based upon that of Jesik et al. (23) who have described in detail the anatomy and histology of the male accessory sex glands of rats. The rat prostate consists of four paired lobes (23, 27, 37): the ventral, dorsal, lateral, and anterior lobes, which are of urogenital sinus origin (37). The anterior prostate is commonly referred to as the *coagulating gland* and, unlike

the other prostate lobes, extends parallel along the paired *seminal vesicles*, which are derived from the Wolffian duct (37, 46). The dorsal and lateral prostate lobes are often referred to as the *dorsolateral prostate* because it is difficult and usually unnecessary to distinguish between these lobes on a routine basis. The dorsal and lateral prostate lobes are morphologically similar (23, 27) and often display a comparable spectrum of pathological changes in the aging rat (7-9, 11). Nevertheless, it is possible to grossly and microscopically distinguish the lateral from the dorsal prostate (23, 27). The *ventral prostate* is anatomically distinct from the dorsolateral prostate (23, 27) and shows a spectrum of lesions that may differ from that found in the dorsolateral prostate (7-9). The tissues that directly surround the prostatic urethra and prostatic utricle are structurally very complex. They consist of the ducts of all four prostate lobes and the seminal vesicles, as well as the deferent ducts and ampullary glands which are both derived from the Wolffian duct (47).

METHODS OF TISSUE SAMPLING AND TRIMMING FOR HISTOLOGIC EXAMINATION

Because of the extraordinary complexity of the male accessory sex gland structures, knowledge of their anatomical relationships and incorporation of this information in tissue sampling and processing protocols is imperative. Vigorous standardization of tissue sampling and trimming methods will consistently provide the pathologist with the same orientation of the tissue and thereby reduce inter- and intra-observer variability.

The accessory sex glands (prostate lobes, coagulating glands, and seminal vesicles) are best removed and fixed *in toto*, together with the urethra and urinary bladder; the bladder can be removed for separate fixation, if required. This approach interferes with weighing individual accessory sex glands. However, there is an easy and accurate way to obtain a measure of accessory sex gland weight. Following removal of these glands *in toto* (prior to fixation), the urinary bladder and all but the intraprostatic part of the urethra are removed and connective tissue is cleaned away. An aggregate accessory sex gland weight can then be obtained. The ventral lobes can be removed by blunt dissection for separate weighing without affecting the structural integrity of the remaining glands; however, this requires knowledge of the anatomical relations and skillful dissection. Removal of the intraprostatic urethra, on the other hand, will interfere with further histological examination of the dorsolateral prostate-ampullary gland complex. In addition, it could cause considerable spillage of seminal vesicle secretion. The latter problem also arises when the seminal vesicles and coagulating glands are dissected away before fixation and leads to high variability in seminal vesicle weights and histological appearance of the tissues.

Correct tissue trimming is critical in the microscopic evaluation of rat accessory sex glands. One such trimming method has been described previously (9, 11). Briefly, it consists of trimming off the urinary bladder, ventral prostates, and seminal vesicle/coagulating gland complexes, and cutting the dorsolateral prostate complex in halves at a right angle to the prostatic urethra. These dorsolateral prostate lobe halves are both embedded and sections will include dorsal and lateral prostate, ampullary glands, prostatic urethra, and prostatic utricle, as well as ducts of the prostate lobes, coagulating glands, and seminal vesicles; the ventral lobes are separately embedded. Alternatively, it is possible to make sections in a para-sagittal plane including dorsolateral lobes and some of the ampullary glands, and, in smaller rats, the ventral lobes; the periurethral region cannot easily be viewed in this approach. It is often neither necessary nor practical to distinguish between ventral and dorsolateral prostate on a routine basis in toxicologic pathology. Nevertheless, it is important to include both ventral and dorsolateral prostate in microscopic examination of the male genital tract, regardless of which tissue trimming method is used, so that the exact lobe localization of lesions can be determined when required. The coagulating glands and seminal vesicles are best examined together. A longitudinal section is preferable to a cross-section because there may be proximal-distal differences in the occurrence of proliferative lesions in these glands. However, one or two cross sections may be sufficient for routine examination. Vigorous standardization of tissue trimming and embedding is more important than the actual methods selected, as long as all prostate lobes (including the coagulating gland) and the seminal vesicles are included for evaluation.

MORPHOLOGY

The rat prostate has four distinct paired lobes. It is neither practical nor necessary in routine toxicologic pathology to discriminate between these lobes when recording prostate lesions, with the exception of the coagulating gland. However, when there appear to be treatment-related effects in a study, it may be important to determine the exact lobe localization of lesions. The ventral and dorsolateral prostate lobes are considered separately here because their spectrum of spontaneous and induced pathological changes differs. The coagulating gland is easily distinguishable from the other prostate lobes and is usually embedded together with the seminal vesicle. The structure of this gland and its spectrum of pathological changes is distinctly different from that of the other prostate lobes. Therefore, it is recommended that the coagulating gland be considered a separate tissue for routine evaluation.

VENTRAL PROSTATE

Hyperplasia (Figures 1-6)

There are basically three morphologically distinct types of hyperplasia that may be found in the ventral prostate of the rat—reactive hyperplasia and two types of non-reactive hyperplastic lesions (functional and atypical). **Reactive hyperplasia** (9, 11) occurs in association with inflammatory cell infiltrate. It consists of a simple thickening of the epithelium to two or more cell layers, but pseudoglandular structures can also be found. The hyperplastic cells may be slightly atypical but are mostly uniform. The occurrence of this lesion parallels that of prostatitis and is usually not separately recorded.

Physiologic or **functional hyperplasia** (9, 11) can be focal, multifocal, or diffuse in the ventral prostate, and is usually found at the periphery of the lobe. It is characterized by crowded tall columnar epithelial cells and by infolding of the lining epithelium into the alveolar lumen. The cells are hyperbasophilic but are otherwise normal in morphology. The amount of intra-alveolar secretion is often decreased. In contrast to reactive or atypical hyperplasia, the epithelium is not multilayered, but the increased infolding can be mistaken for cribriform growth. Functional hyperplasia may be accompanied by diffuse enlargement of the gland, but glandular enlargement is most often the result of hypersecretion or obstruction of the outflow of secretum rather than hyperplasia. A mild degree of functional hyperplasia is frequently present in adult rats, but its presence is rarely recorded as a spontaneous finding.

Pathologic or **atypical hyperplasia** (9, 11, 29, 38, 50) is a focal, often multifocal, lesion that involves single or sometimes two or three adjacent alveoli; prostatic ducts are occasionally affected. It does not occur at a specific localization within the lobe. The lesion consists of epithelial proliferations that follow the alveolar lining and do not obliterate the alveolar lumen, although papillary formations can be found. The epithelium is two or more cells layers thick and a cribriform pattern is common. Normal alveolar architecture is not disturbed and there is no fibrous capsule formation or compression of surrounding tissue. The affected alveoli have a normal amount of secretion.

In comparison with normal epithelial cells, atypical cells have lost their polarity, often have an increased cytoplasmic/nuclear ratio, and may be somewhat enlarged. The cytoplasm is usually slightly eosinophilic to hypochromatic and the nucleus is usually slightly hyperchromatic, sometimes with prominent nucleoli. Cellular and nuclear pleomorphism is minimal and mitotic figures are infrequent. The earliest change is a focal loss of cellular polarity and increase in cellularity, usually in an area where the epithelial cells are columnar and somewhat hypereosinophilic. Abrupt changes from normal to atypical hyperplastic epithelium occur as well as more gradual transitions via increasingly tall columnar epithelial cells. In the latter case, the cells have hypereosinophilic cytoplasm and basally-located hyperchromatic nuclei, and are sometimes arranged in two or three layers. Focal areas with increased cellular atypia (dysplasia) and focal squamous metaplasia can occur within areas of atypical hyperplasia. Grading of atypical hyperplasia can be done on the basis of a combination of the number of alveoli affected and the extent of the lesions.

Squamous Metaplasia

Focal squamous metaplastic changes of the ventral prostate are rare spontaneous lesions, but may be induced by certain carcinogens (35, 36). These types of lesions consist of multilayered squamous epithelium. There is reduced or no secretion in affected alveoli. Keratinization may be present but is rare. Diffuse squamous metaplasia has not been reported to occur spontaneously.

Adenoma (Figures 7-10)

Spontaneously occurring and chemically induced adenomas of the ventral prostate are usually not grossly visible. These tumors (8, 11, 29, 38, 50) are intra-alveolar epithelial proliferations that completely or almost completely fill the lumen of one to several adjacent alveoli. Distortion of normal alveolar architecture and compression of surrounding tissue are hallmark features, but they vary widely in severity. A thin fibrous capsule can completely or partly surround the lesion, particularly in the case of large adenomas. There is sometimes extension along the epithelial lining of adjacent alveolar lumina or ducts, but the lesions are not clearly invasive. Adenomas can occur multifocally at any location in the ventral prostate lobe. The epithelial cells in adenomas are characteristically arranged in a cribriform pattern, with some occasional comedo growth patterns and solid or microglandular-tubular areas. The cells have completely lost their normal polarity and they are mostly polygonal. Basal cells are absent. The cells are often enlarged and have an increased cytoplasmic/nuclear ratio and their cytoplasm is eosinophilic in comparison with normal epithelium. Their nuclei are round to oval, often slightly hyperchromatic, mildly to moderately pleomorphic, and usually enlarged. Focal areas with increased dysplasia and some squamous metaplasia may be present, particularly in larger adenomas. A few mitotic figures, sometimes in abnormal configurations, are common. There is usually no inflammation.

There is a single report of a cystadenoma of the ventral prostate (8, 36). This tumor consists of a conglomerate of cystic spaces that is sharply demarcated with a thin fibrous capsule and compresses surrounding tissue. There are many infoldings and papillary projections into the lumen of the cysts. The epithelial cells are flat to cuboidal and have hyperchromatic cytoplasm and nuclei.

Adenocarcinoma (Figures 11 & 12)

Adenocarcinomas of the ventral prostate (7, 11, 38, 50) are epithelial proliferations that vary in size from approximately five alveoli to the entire ventral lobe. Large adenocarcinomas often markedly distort the architecture and gross shape of the ventral prostate. Hemorrhagic areas and focal necrosis are common. Macroscopically detectable adenocarcinomas have been described in aging ACI/segHapBR rats as hemorrhagic and pigmented nodular areas (49). Small adenocarcinomas may be grossly apparent. Microscopically, a distinct fibrous capsule is often present and sharply demarcates the tumor from adjacent normal tissue. Fibrous stromal septa dividing the tumor into pseudolobules are common. Invasive growth is generally limited to invasion of the tumor capsule and surrounding alveoli and stroma, whereas perineural invasion, blood vessel infiltration, and penetration of the prostatic capsule are infrequent. Cribriform, comedo, and solid growth patterns predominate. Cellular atypia is increased in comparison with adenomas and atypical hyperplasias, and it tends to increase further with increasing tumor size (49). Poorly-differentiated epithelium can be found in solid areas (38). In comparison with normal ventral prostate epithelium, the cells are often clearly pleomorphic and enlarged, and have a higher cytoplasmic/nuclear ratio, hyperchromatic and eosinophilic cytoplasm, and larger nuclei with prominent and sometimes multiple nucleoli. There are often some mitotic figures and a mixed cell inflammatory infiltrate is frequently present. Metastases from adenocarcinomas of the ventral prostate have not been reported (38, 50).

Squamous Cell Carcinoma

Squamous cell carcinomas of the ventral prostate induced by some chemical carcinogens have been described in the literature (35, 36, 39). These lesions consist of epidermoid cells invading surrounding tissue. Blood vessel penetration and metastases give additional indication of malignancy. Keratinization is sometimes present.

DORSOLATERAL PROSTATE

Hyperplasia (Figure 13)

As with the ventral prostate, three morphologically distinct types of hyperplasia may be found in the dorsolateral prostate—reactive, functional, and atypical hyperplasia. **Reactive hyperplasia** (9, 11) is always combined with inflammatory cell infiltrate and consists of a simple thickening of the epithelium to two or more cell layers. Sometimes pseudoglandular structures are present which may have some cellular atypia. Reactive hyperplasia is usually not recorded separately from prostatitis.

Physiologic or **functional hyperplasia** (9, 11) can be found focally or multifocally at the periphery of the lobe. It is difficult to detect due to the variability in the morphology of the normal dorsolateral prostate. As in the ventral lobe, it is characterized by crowded, slightly hyperbasophilic, but otherwise normal, epithelial cells that are cuboidal to columnar. It is also characterized by increased infolding of the lining epithelium into the alveolar lumen. The amount of intra-alveolar secretion is usually decreased, and the increased infolding can be mistaken for cribriform growth. A mild degree of functional hyperplasia is occasionally present in adult rats, but its presence is rarely recorded as a spontaneous finding.

Pathologic or **atypical hyperplasia** of the dorsolateral prostate is very rare. There is considerable variation in the appearance of these lesions (9, 11, 25, 26, 31, 43, 44). The lesion may vary from intra-alveolar microgland formation with atypical cells arranged in a single layer to multilayered areas consisting of disorderly piled-up, enlarged, hypochromatic cells with large pale nuclei, sometimes with a cribriform growth pattern. Atypical hyperplasia can occur in the alveoli as well as in the ducts. It is difficult if not impossible to distinguish between atypical hyperplasia with a distinct inflammatory component and reactive hyperplasia, which occurs frequently in the dorsolateral prostate. Atypical hyperplasia may sometimes show continuous morphological progression into early stage adenocarcinomas. (11, 43, 44).

Squamous Metaplasia (Figure 14)

Focal metaplastic changes of the prostate, occasionally with some keratinization, occur in aging rats often as a reaction to either the presence of large concretions in the dorsolateral prostate ducts or inflammatory processes (11). Diffusely occurring squamous metaplasia has not been reported to occur spontaneously in the rat dorsolateral prostate. There is a report of induction of diffuse squamous metaplasia by estrogen in rat dorsolateral prostate ducts (4).

Seminal Vesicle-Like Metaplasia

Seminal vesicle-like metaplasia (11) is a change that is characterized by the replacement of the normal epithelium of the dorsolateral prostate by epithelial cells that closely resemble seminal vesicle epithelium. The cells in this lesion are columnar with somewhat elongated, strongly basophilic, basal nuclei. There is a distinct increase in the number of cells per unit length of basement membrane as compared with normal epithelium, and there often is an increase in the number of glandular infoldings. Areas of atypical hyperplasia may also occur in this lesion.

Adenoma (Figure 15)

There is a single report of an adenoma of the dorsolateral prostate (8). It is described as a microglandular-tubular proliferation that does not invade surrounding tissues. It has a pronounced fibrous capsule, abnormal alveolar architecture, and slightly compressed surround-

ing prostatic tissue. The microglands are lined with one to three layers of cells, which are columnar and have hypochromatic, basophilic cytoplasm and hypochromatic, enlarged nuclei with sometimes conspicuous nucleoli. There are no basal cells. Cribriform adenomas, which are morphologically similar to those in the ventral prostate, may also occur in the dorsolateral prostate of carcinogen-treated rats, but these are very rare (11).

Adenocarcinoma (Figures 16 - 19)

Adenocarcinomas of the dorsolateral prostate have a glandular growth pattern with an often abundant amount of stromal tissue (7, 11, 29, 36, 43). Cribriform and comedo growth patterns are very rare (11) and have not been reported in the literature. The glandular-type carcinomas display a considerable variation in degree of differentiation, both from tumor to tumor and within a single carcinoma. Well-differentiated carcinomas are composed of small glandular and sometimes tubular structures, consisting of a single or occasionally double layer of neoplastic epithelial cells. Less differentiated tumors have sheets, solid fields, and often cords of neoplastic cells embedded in connective tissue stroma. There are no basal cells. The neoplastic cells vary in size, cytoplasmic/nuclear ratio, and staining properties of cytoplasm and nuclei. There are often prominent nucleoli and a moderate number of mitotic figures. Signs of secretory activity can be found in well-differentiated carcinomas. A mixed cell to predominantly polymorphonuclear inflammatory infiltrate is common in these tumors, and some central necrosis may be present. These carcinomas are invasive, infiltrating blood vessels and perineural spaces and invading into adjacent normal prostate, prostatic capsule, and surrounding tissues. They have often invaded into several accessory sex gland structures, impeding determination of the exact site of origin. Adenocarcinomas often metastasize, primarily to the regional lymph nodes and lungs, but also to the liver and other tissues (15,16,44), indicating that both hematogenic and lymphogenic dissemination can occur. Skeletal metastases have not been described. The histogenesis of these carcinomas has not been described in detail, but they arise *de novo* from atypical hyperplasias rather than via an adenoma stage (7, 11, 43, 44).

Squamous Cell Carcinoma

There is one report of a spontaneous squamous cell carcinoma in the rat dorsolateral prostate (29). This type of carcinoma can be induced by some chemical carcinogens or hormonal treatments (21, 35, 36, 39). These lesions are characterized by epidermoid cells invading surrounding tissue. Blood vessel penetration and metastases give additional indication of malignancy. Keratinization is sometimes present.

COAGULATING GLAND

Hyperplasia (Figure 20)

Two types of hyperplasia have been described in the coagulating gland of male rats—reactive hyperplasia and atypical hyperplasia. **Reactive hyperplasia** (11) is always combined with inflammatory cell infiltrate and consists of a simple thickening of the epithelium to two or more cell layers. Sometimes pseudoglandular structures are present which may have some cellular atypia. It is usually not recorded as a separate lesion from inflammation.

Pathologic or **atypical hyperplasia** (11, 21) of the coagulating gland is rare. It occurs in areas with increased glandular infolding and consists of cells that have lost normal polarity, are slightly enlarged, and have a hypochromatic cytoplasm. The nuclei are usually hypobasophilic but occasionally are hyperbasophilic. The cells are usually not piled-up and follow the lining of the glandular infoldings, but cribriform papillary hyperplasia can also occur (11). Atypical hyperplasia may sometimes show continuous morphological progression into early stage adenocarcinomas. (11, 43, 44).

Squamous Metaplasia (Figure 21)

Focal squamous metaplasia, occasionally with keratinization, can occur in the coagulating gland of aging rats. Usually, it occurs in reaction to inflammation. Diffuse squamous metaplasia of the coagulating gland has not been reported to occur spontaneously but has been induced by perinatal estrogen treatment (1, 2) and estrogen administration to adult rats (12), similar to what has been described for mice (3).

Seminal Vesicle-Like Metaplasia (Figure 22)

Seminal vesicle-like metaplasia (11) is characterized by the replacement of the normal epithelium of the coagulating gland by epithelial cells that closely resemble or are indistinguishable from seminal vesicle epithelium. The cells in this lesion are cylindrical with somewhat elongated, strongly basophilic, basal nuclei. The number of cells per unit basement membrane is distinctly increased in comparison with normal epithelium, and the amount of glandular infolding is usually also increased. Atypical hyperplasia may occur within this lesion.

Adenoma (Figure 23)

Induced adenomas of the coagulating gland are cribriform lesions which are morphologically similar to those occurring in the ventral prostate (11). These adenomas are not grossly visible. Demarcation, compression of surrounding tissue, disruption of normal glandular architecture, and cellular atypia within the lesion can be used as criteria to distinguish between adenoma and hyperplasia. Spontaneous adenomas of the coagulating gland have not been reported in the literature.

Adenocarcinoma (Figures 24–26)

Induced adenocarcinomas of the coagulating gland have a glandular growth pattern with often abundant scirrhous stromal tissue and desmoplasia. These tumors are morphologically similar to those found in the dorsolateral prostate (11, 21, 43, 44). Cribriform and comedo growth patterns, similar to those occurring in the ventral prostate, can also occur in the coagulating gland, but are extremely rare (11). Spontaneous coagulating gland adenocarcinomas have not been reported in the literature.

Glandular pattern tumors probably develop *de novo* from areas of atypical hyperplasia rather than from adenomas (11, 21, 43, 44). They invade into the coagulating gland capsule and surrounding tissues rather than into the glandular lumen. These adenocarcinomas vary considerably in degree of differentiation from well-differentiated to poorly-differentiated or anaplastic, and they can metastasize. They may develop from the glandular portion of the coagulating gland as well as from its ducts. When these tumors are larger and have invaded into other accessory sex gland structures, it may be difficult or impossible to determine the exact site of origin.

Squamous Papilloma

Squamous papillomas can occur in the ducts of the coagulating gland but are extremely rare, even in carcinogen-treated rats (11). These lesions consist of hyperplastic, keratinizing squamous epithelium arranged on stalks protruding into the lumen of the ducts. The ducts are often distended due to the presence of the papilloma and abundant keratin production.

SEMINAL VESICLE

Hyperplasia (Figures 27 & 28)

Two types of hyperplasia may be found in the seminal vesicle of the rat—reactive hyperplasia and atypical hyperplasia. **Reactive hyperplasia** is always combined with inflammatory cell infiltrate and often consists of a thickening of the epithelium with or without pseudoglandular structures. The hyperplastic cells are often slightly atypical. It is usually not recorded separate from vesiculitis.

Atypical hyperplasia of the seminal vesicle consists of pale cells that have lost normal cellular polarity and display moderate nuclear and cellular atypia with considerable variation in size and shape of the cells (10, 15, 18, 40, 41). The cells are disorderly arranged and are often piled-up in solid, microgland, and/or cribriform patterns. Atypical hyperplasia may sometimes show continuous morphological progression into early stage adenocarcinomas. (11, 43, 44).

A variation of this focal lesion is a combination of hyperplasia and cellular hypertrophy, where the hypertrophy is more prominent than the hyperplasia, particularly in small lesions. In this variation, there is only slight cellular atypia and no pleomorphism, and the cells follow the normal glandular contours. The lesion is well-demarcated with abrupt transitions from normal to affected epithelium. It sometimes contains areas with increased cellular atypia but it has not been found to be associated with carcinoma (10, 11, 40, 41).

Squamous Metaplasia

Squamous metaplasia may be focal or diffuse. It consists of multilayered squamous epithelium, and there is reduced or no secretion in affected alveoli. Keratinization may be present, but is rare. If the lesion is focal, it is often associated with large intra-alveolar or intraductal concretions or inflammation. Focal squamous metaplasia can occur as a reaction to the presence of inflammation in the seminal vesicle. Spontaneous diffuse squamous metaplasia has not been reported, but it may be induced by estrogen in the rat seminal vesicle (4).

Adenoma

There is one report that describes the morphology of a spontaneous seminal vesicle adenoma (6, 46). This lesion consists of epithelium arranged in a papillary and glandular pattern that compresses surrounding tissue. There is some nuclear atypia and cellular crowding, but the cells otherwise closely resemble normal epithelium. Demarcation, compression of surrounding tissue, disruption of normal glandular architecture, and cellular atypia within the lesion may serve as criteria to distinguish adenoma from hyperplasia.

Adenocarcinoma (Figures 29 & 30)

Adenocarcinomas of the seminal vesicle usually have a glandular growth pattern with an abundant amount of desmoplasia of scirrhous stromal tissue. These carcinomas have a morphology similar to that found in the dorsolateral prostate, and vary considerably in degree of differentiation (10, 11, 18, 21, 43, 44). Adenocarcinomas invade into the glandular capsule and surrounding tissues but not into the glandular lumen, and they can metastasize. These tumors are more likely to develop from the glandular portion of the gland than from its ducts. When these tumors are larger and have invaded into other accessory sex gland structures, it may be difficult or impossible to determine the exact site of origin.

Squamous Papilloma

Squamous papillomas can occur in the ducts of the seminal vesicle of carcinogen-treated rats but are rare (11). These lesions consist of hyperplastic, keratinizing squamous epithelium arranged on stalks protruding into the lumen of the ducts. The ducts are often distended due to the presence of the papilloma and abundant keratin production.

AMPULLARY GLAND

Little is known about spontaneous or induced lesions in the rat ampullary gland. Spontaneously occurring neoplastic lesions of the ampullary gland have not been described, nor have they been observed in carcinogen-treated rats (11).

Hyperplasia (Figures 31 & 32)

Two types of hyperplasia have been described in the ampullary gland of male rats—reactive hyperplasia and atypical hyperplasia. **Reactive hyperplasia** associated with chronic inflammation probably results from sperm reflux and can ultimately develop into sperm granulomas (11, 15, 28). **Atypical hyperplasia** may also occur in the ampullary gland, but this lesion has only been found in carcinogen-treated rats (11). Such atypical hyperplasia of the ampullary gland consists of proliferation of small cells. Some of these cells may be similar to normal ampullary epithelium but some cellular atypia is always present. These cells are enlarged and have a pale cytoplasm and nuclei. The epithelium is thickened to up to seven cell layers and intra-epithelial microglandular formations are frequent in severe cases.

MESENCHYMAL ACCESSORY SEX GLAND TUMORS

A variety of spontaneous and chemically induced mesenchymal tumors can occur in the rat accessory sex glands: leiomyosarcoma, fibroma, fibrosarcoma, paraganglioma, neurofibroma, neurofibrosarcoma, histiocytic sarcoma, malignant fibrous histiocytoma, hibernoma, mesothelioma, undifferentiated sarcoma, and metastases such as from generalized lymphomas (11, 15, 20, 29, 45). Their morphology does not differ from similar tumors found in other organs.

DISCUSSION

Spontaneous proliferative lesions of most male accessory sex glands occur in low frequency in aging rats (11). The only gland that shows a significant and, in some rat strains, considerable incidence of proliferative changes is the ventral prostate lobe (11, 22, 38, 50). Little doubt has been expressed that adenoma of the ventral prostate develops from atypical hyperplasia and that carcinoma develops from adenoma (11, 38, 50). While it is relatively easy to make a distinction between hyperplasia, adenoma, and carcinoma in most accessory sex glands, such distinction is difficult in the ventral prostate. All stages, from very early hyperplasia to adenoma or invasive carcinoma, have been observed in aged rats without a clear separation between these lesions (11, 38, 50). This suggests that the development of carcinomas in the ventral prostate is a continuum without discrete steps. Nevertheless, with increasing size of the proliferative lesions, there is an increase in the occurrence of focal dysplastic areas and of comedo and solid growth patterns, while cellular atypia increases slightly (11, 38, 50).

Distinction between atypical hyperplasia, adenoma, and carcinoma in the ventral prostate is thus to some extent arbitrary, particularly in borderline cases. Hyperplasia of the ventral prostate has therefore sometimes been classified as early carcinoma *in situ*, and adenoma as advanced carcinoma *in situ* or early carcinoma (24, 40). These small lesions may have all the morphological characteristics of carcinoma except clear invasive growth, which might justify classifying them as early carcinoma. This may be appropriate in a basic research setting, but for the proper interpretation of long-term toxicologic studies it is essential to distinguish between atypical hyperplasia, benign tumors, and malignant tumors. Furthermore, there is no evidence that all atypical hyperplasias will eventually progress to larger and expansile tumors (adenoma), or that all adenomas will ultimately progress to more bulky and invasive neoplasms (carcinoma), or that these lesions even have the capability to do so. Therefore, it is proposed to apply a distinction between hyperplasia, adenoma, and carcinoma using standard morphological criteria that are used for other organs in rodent species until there is more insight into the biologic behavior of these proliferative lesions (5).

The proposed practical approach to distinguish adenoma from atypical hyperplasia and adenoma from carcinoma in the rat ventral prostate is presented in Table 1. A combination of several criteria listed in this table should be used to make these distinctions. It is recommended that the term adenoma be reserved for proliferations that completely obliterate the lumen of one or more alveoli, compress surrounding tissue, and disturb normal alveolar architecture. Capsule formation and the presence of comedo growth patterns provide further indications for the diagnosis of neoplasia. Invasive growth and metastases are conclusive criteria for separating adenomas from carcinomas. However, since most ventral prostate adenocarcinomas are of low grade malignancy, size may be an additional criterion. It is likely that large tumors involving more than ten alveoli have invaded through alveolar walls, although there may be no clear-cut histologic evidence for invasive growth other than fibroplasia. In addition, distinct cellular and nuclear pleomorphism and comedo growth patterns should also be present for the diagnosis of carcinoma.

Discrete precursor lesions of carcinomas of the dorsolateral prostate, coagulating gland, and seminal vesicle are not well defined because atypical hyperplasia in these structures is not as well delineated as is atypical hyperplasia of the ventral prostate. Current evidence indicates that adenocarcinomas in these structures develop

de novo and do not involve a benign (adenoma) stage. Carcinomas have been observed to develop early from small areas of atypical hyperplasia in all these glands (11, 12, 43, 44). Although classification as carcinoma *in situ* (6, 17) is perhaps suitable for some intra-epithelial hyperplastic lesions with a high degree of atypia and pleomorphism, the use of this term is not recommended because it leads to confusion about the distinction between hyperplasia and neoplasia.

The localization and the site of origin of prostatic carcinomas is usually easy to determine for tumors of the ventral prostate. However, the site of origin of carcinomas in the dorsolateral prostate is often unclear. Tumors in this region can potentially arise from any of the following epithelial structures: dorsolateral prostate, ampullary gland, seminal vesicle, coagulating gland, the ducts of these glands and of the ventral prostate, prostatic utricle, urethra, and periurethral glands. For practical purposes, only tumors that are clearly located in a specific gland should be classified as prostatic, coagulating gland, or seminal vesicle tumors. Tumors that are larger and whose site of origin and localization is not clear could be classified as accessory sex gland tumors or as seminal vesicle/coagulating gland tumors if they only involve these glands. Very large tumors that involve other pelvic structures as well as the accessory sex glands could be classified as pelvic (cavity) tumors or accessory sex gland tumors.

Observer bias probably plays an important role in the detection of small proliferative lesions in the rat prostate and may lead to under diagnosis due to missed lesions from improper trimming. Correct tissue trimming and processing methods are critical in the microscopic evaluation of rat accessory sex glands. Regardless of the tissue trimming method used, it is important to include both the ventral and dorsolateral prostate in microscopic examination of the male genital tract of rats. This allows for the determination of the exact lobe localization of proliferative lesions when treatment-related effects are suspected.

Information about the spontaneous occurrence of proliferative lesions of the rat male accessory sex glands and about possible etiology and experimental induction of these lesions can be found elsewhere (7, 11, 13, 39). The incidence of spontaneous proliferative lesions of the ventral prostate varies widely among rat strains (7-9, 11, 22, 29, 38, 50). This may point to genetic factors being involved in their etiology (13). There may be genetically controlled differences between strains in susceptibility to background levels of environmental carcinogens, but there are also data suggesting that genetically determined high plasma testosterone levels or high testosterone/estrogen ratios are related to high risk (22). Spontaneous proliferative lesions of the dorsolateral prostate, coagulating gland, seminal vesicle, and ampullary gland are rare (11). However, the following lesions can be induced by hormones, (1, 25, 26, 30, 31, 34) chemical carcinogens, and combined treatment with these types of compounds (4, 14–18, 21, 33, 36, 40–44, 46): physiological/functional hyperplasia of ventral and dorsolateral prostate; seminal vesicle-like metaplasia of the coagulating gland and dorsolateral prostate; squamous metaplasia, atypical hyperplasia, adenoma, and carcinoma of all glands; squamous papilloma of the coagulating gland and seminal vesicle; and squamous cell carcinoma of the ventral and dorsolateral prostate (7-9, 11-13, 48). The rate of occurrence of these lesions depends in part on the rate of epithelial cell proliferation during carcinogen exposure and on the levels of circulating androgens (14, 15, 33, 36, 43).

RECOMMENDED NOMENCLATURE AND DIAGNOSTIC CRITERIA

HYPERPLASIA

Reactive Hyperplasia

Occurs in all accessory sex glands

1. Occurs in association with inflammatory cell infiltrate
2. Simple thickening of the epithelium to two or more cell layers
3. Pseudoglandular structures may be present
4. May have some cellular atypia
5. Usually not recorded separately from inflammation

Functional Hyperplasia

Occurs in ventral and dorsolateral prostate

1. Focal, multifocal, or diffuse, usually located in periphery of the gland
2. Increased infolding in alveolar lumen
3. Epithelial cell height is increased and cytoplasm is hyperbasophilic, but cells are otherwise normal
4. Epithelium is not multilayered
5. Amount of intra-alveolar secretum is often decreased

Atypical Hyperplasia

Occurs in all accessory sex glands

1. Is characteristically a focal or multifocal lesion occurring in single or 2-3 adjacent alveoli
2. Does not disturb normal glandular architecture and does not compress surrounding tissue
3. Atypical cells follow alveolar lining in one or more growth patterns (see 7) and they do not obliterate alveolar lumen, but papillary growth occurs
4. Atypical cells may merge abruptly with normal epithelium or merge gradually without clear demarcation
5. Cells characteristically have lost normal cellular polarity, are often enlarged, and have a pale (or in the case of the ventral prostate, pale to eosinophilic) cytoplasm and often hyperchromatic nuclei

6. Mitotic index is very low
7. Cells in the lesion are disorderly arranged; their growth pattern differs for the different accessory sex glands:
   - ventral prostate: multilayered, often cribriform pattern
   - dorsolateral prostate: multilayered to intra-epithelial microgland pattern
   - coagulating gland: cells are not piled-up but follow normal alveolar contours, or in cribriform pattern (rare)
   - seminal vesicle: multilayered, solid field, intra-epithelial microgland, and/or cribriform pattern; alternatively, cells are enlarged and pale with minimal atypia, are not piled-up but follow normal glandular contours, and are sharply demarcated from normal tissue
   - ampullary gland: multilayered, intra-epithelial microgland, and/or cribriform pattern

SQUAMOUS METAPLASIA

Occurs in all accessory sex glands except the ampullary gland

1. Focal or diffuse
2. Consists of multilayered squamous epithelium
3. There may be keratinization (rare)
4. There is less than normal or no secretion left in affected alveoli
5. If focal, often associated with large intra-alveolar or intraductal concretions or inflammation

SEMINAL VESICLE-LIKE METAPLASIA

Occurs in coagulating gland and dorsolateral prostate

1. Focal lesion
2. Increased number of glandular infoldings lined with a single layer of crowding cells
3. Cells characteristically resemble seminal vesicle epithelium and are high cylindrical with basally located, oval to elongated nuclei and basophilic cytoplasm
4. Affected epithelium abruptly merges with normal epithelium
5. No compression of surrounding tissue

ADENOMA

Occurs in all accessory sex glands except the ampullary gland

1. Well-demarcated lesion that completely obliterates the lumen of one to several (<10) alveoli, compresses surrounding tissue, and distorts normal alveolar architecture
2. May have a fibrous capsule and fibrous septa
3. Cells that have lost normal polarity are disorderly arranged in one of the following growth patterns:
   - cribriform pattern with occasional comedo pattern (ventral prostate, occasionally dorsolateral prostate and coagulating gland)
   - microglandular pattern (dorsolateral prostate)
   - cystadenoma pattern (ventral prostate, rare)
4. The cells in cribriform areas are mildly pleomorphic, are enlarged with eosinophilic cytoplasm, and have round to oval, hyperchromatic nuclei; mitotic index is low
5. The cells in microglandular areas are moderately pleomorphic, are flat to cuboidal, and have pale cytoplasm and enlarged nuclei
6. Basal cells are absent

ADENOCARCINOMA

Occurs in all accessory sex glands except the ampullary gland

1. Local invasion, penetration of glandular capsule, fibroplasia, and metastasis indicate malignancy
2. The growth pattern is either predominantly cribriform or glandular
3. Cribriform adenocarcinomas (ventral prostate and, rarely, coagulating gland):
   - May lack clear invasive growth and metastases; size (> 10 alveoli) in combination with the presence of comedo patterns and marked cellular and nuclear pleomorphism can be used as additional diagnostic criteria
   - Have a distinct fibrous capsule with fibroplasia, some mononuclear inflammatory cell infiltrate, and a variable mitotic index
5. Glandular type adenocarcinomas (dorsolateral prostate, coagulating gland, and seminal vesicle):
   - Have variable, sometimes marked, amount of scirrhous stroma and often show fibroplasia
   - Vary in degree of differentiation from forming well-differentiated glands with low mitotic index to strands and sheets of poorly-differentiated cells with moderate mitotic activity
6. Basal cells are absent

SQUAMOUS PAPILLOMA

Occurs in ducts of coagulating gland and seminal vesicle

1. Consists of hyperplastic, keratinizing squamous epithelium arranged on stalks protruding in lumen of duct
2. Duct often distended due to presence of papilloma and abundant keratin production

SQUAMOUS CELL CARCINOMA

Occurs in ventral and dorsolateral prostate

1. Consists of epidermoid cells invading surrounding tissue
2. Blood vessel penetration and metastases give additional indication for malignancy
3. Keratinization may be present

MESENCHYMAL TUMORS

The morphology of the following tumors is similar to that found in other organs:

- Fibroma
- Hibernoma
- Histiocytic sarcoma
- Fibrosarcoma
- Leiomyosarcoma
- Mesothelioma
- Metastases of lymphoma/leukemia
- Neurofibroma
- Neurofibrosarcoma
- Paraganglioma
- Undifferentiated sarcoma

ACKNOWLEDGMENTS

This work was supported in part by the following grants to MCB: PHS Grants No. CA43151 and CA48084 from the National Cancer Institute.

Table 1

Morphologic Criteria to Distinguish Atypical Hyperplasia, Adenoma, and Adenocarcinoma of the Ventral Prostate in Male Rats*

Morphologic Feature	Atypical Hyperplasia	Adenoma	Adenocarcinoma
Obliterated alveolar lumen	No	Yes	Yes
Distorted normal architecture	No	Yes	Yes (marked)
Compressed surrounding tissue	No	Yes	Yes
Invasive growth	No	No	Yes
Capsule formation	No	Sometimes	Often with marked fibroplasia
Growth pattern	Cribriform	Predominantly cribriform, also solid and comedo	Cribriform, solid, and (always) comedo
Degree of pleomorphism (atypia)	Mild	Mild to moderate	Mild to marked
Size	One to a few adjacent alveoli	One to several adjacent alveoli	Several to many adjacent alveoli
Central necrosis	No	No	Frequently
Inflammatory infiltrate	No	Occasionally	Frequently

*Adapted in part from Mitsumori and Elwell (29) and Bosland (7, 8, 11)

Dixon D, Leininger JR, Valerio MG, Johnson AN, Stabinski LG, and Frith CH (1999). Proliferative lesions of the ovary, uterus, vagina, cervix and oviduct in rats, URG-5. In: **Guides for Toxicologic Pathology**, STP/ARP/AFIP, Washington, DC.

Proliferative Lesions of the Ovary, Uterus, Vagina, Cervix and Oviduct in Rats

D. Dixon,[1] J.R. Leininger,[1] M.G. Valerio,[2] A.N. Johnson,[3] L. G. Stabinski,[4] and C.H. Frith[5]

[1]National Institute of Environmental Health Sciences, Research Triangle Park, North Carolina
[2]Rhone-Poulenc Rorer Central Research, Collegeville, Pennsylvania
[3]R.W. Johnson Pharmaceutical Research Institute, Raritan, New Jersey
[4]Merck & Co., Inc., West Point, Pennsylvania
[5]Toxicology Pathology Associates, Little Rock, Arkansas

INTRODUCTION

Primary ovarian tumors are generally uncommon in rat strains used in toxicologic studies; however, these tumors have been reported to occur with some frequency in certain strains (4, 9). Ovarian tumors have been experimentally induced in rats (12, 23, 32). Primary spontaneous tumors of the uterus (except for uterine stromal polyps in some strains), vagina, cervix, or oviduct are uncommon in rats typically used in toxicologic studies, although certain experimental strains such as the Eker and Donryu rats have been reported to develop spontaneous uterine tumors (8, 13, 19). There are few chemically related effects observed in these organs in chronic carcinogenicity studies. Although various tumors throughout the reproductive tract have been induced experimentally, most spontaneous tumors of the female rat reproductive tract are incidental findings at necropsy or routine histologic screening, (6, 11, 15, 17, 18).

Non-neoplastic proliferative lesions of the ovary, uterus, vagina, cervix and oviduct are infrequent in most strains of rats commonly used in toxicologic studies (1, 3, 9, 11, 15). Although the incidence of spontaneous non-neoplastic proliferative lesions increases with age, the incidence of these lesions overall is low (3, 15).

The following classification scheme is based upon morphologic characteristics in hematoxylin and eosin (H&E) stained preparations. The tumors of the ovary are divided into three major categories according to their presumed histogenesis and direction of differentiation: epithelial tumors, sex cord-stromal tumors, and germ cell tumors. The tumors of the uterus, vagina, cervix and oviduct are divided into epithelial and nonepithelial based on presumed histogenesis. The classification scheme is based upon that proposed by the National Toxicology Program and the WHO Histologic Classification of Ovarian Tumors (2, 15, 18).

MORPHOLOGY
OVARY

NEOPLASMS OF EPITHELIAL ORIGIN

Cystadenoma/Cystadenocarcinoma (Figures 1-4)

Grossly, cystadenomas may present as single or multiple ovarian cysts, whereas cystadenocarcinomas appear as large cystic masses. Microscopically, cystadenomas

Address correspondence to: Society of Toxicologic Pathologists, 19 Mantua Road, Mt. Royal, NJ, 08061.

have papillary infoldings lined by cuboidal or columnar epithelium. The lesions are usually unilateral and range from microscopic to over a centimeter in diameter. Single or multiple fronds protrude from the cyst wall into the lumen. Diagnosis of cystadenocarcinoma is based upon atypia, multilayering, local invasion, or peritoneal metastases.

Cystadenoma must be differentiated from papillary hyperplasia of a cyst lining by the presence of distinct fronds in the case of the former, and simple infoldings of hyperplastic epithelium in the latter. Also, hyperplasia is usually diffuse and characterized by infoldings of epithelium that have short unbranched papillary extensions; whereas, neoplastic papillae are focal in origin and more structurally complex.

Tubulostromal Adenoma/Tubulostromal Carcinoma (Figures 5 & 6)

Tubulostromal adenomas consist of tubules lined by cuboidal epithelium that resembles ovarian surface epithelium. These lesions vary from microscopic to several centimeters in diameter and are frequently bilateral. Tubules may be identified that are continuous with downgrowths of the surface epithelium. The tubules may be interspersed between packets of variably vacuolated or luteinized cells of probable sex cord origin. The sex cord component is variable and may form a major component of the tumor, which may lead to the primary diagnosis being of the sex cord component.

Differentiating tubulostromal adenoma from epithelial hyperplasia is difficult. Criteria for adenoma include: a distinct mass of well-differentiated tubulostromal elements and compression of the adjacent tissue. A diagnosis of tubulostromal carcinoma is based upon metastasis, local invasion, and/or high mitotic index. Few or numerous cysts with blood or thrombi have been reported in tubulostromal carcinomas.

Mesothelioma (Figures 7 & 8)

These tumors resemble mesotheliomas in other sites and are composed of cuboidal to columnar epithelium in a papillary or frond-like pattern on the surface of the ovary or within the ovarian bursa. Malignant mesotheliomas in the Sprague-Dawley rat resemble adenocarcinomas, but upon close examination have fronds on the surface of the ovary which extend into cyst-like spaces of the primary mass.

NEOPLASMS AND NON-NEOPLASTIC PROLIFERATIVE LESIONS OF OVARIAN SEX CORD-STROMAL ORIGIN

Hyperplasia

Hyperplasia of the sex cord-stroma is characterized by one or more foci or a diffuse increase in granulosa, luteal, or thecal cells as pure or mixed populations. The ovaries may be marginally enlarged with a diffuse, bilateral, hyperplastic change, or foci may arise in atrophied ovaries with little evidence of compression.

Differentiation between hyperplasia and adenoma of the sex cord-stromal cells is difficult. Focal small lesions up to a few (approximately 2-3) mm in diameter are considered hyperplastic and larger lesions are considered neoplasms. When the change is diffuse and bilateral, a more dramatic change such as a 2- to 3-fold increase in ovarian size is used as the criterion to shift a diagnosis of hyperplasia to neoplasia. Cellular pleomorphism is not a good criterion for separating hyperplasia from neoplasia because the cells of sex cord-stromal tumors are often monomorphic.

Granulosa Cell Tumor (Figures 9-12)

These tumors are usually unilateral but can be bilateral. They vary greatly in size and tend to be solid with a smooth or slightly lobulated surface. They grow in a variety of histological patterns including solid sheets, cystic, pseudofollicular, trabecular, and sertoliform. The tumor cells resemble normal granulosa cells with round to oval nuclei, coarsely stippled chromatin, and scant cytoplasm. There may be a variable picture with thecal cell and/or luteal cell areas in the tumor, but granulosa cells predominate. Fibroblasts, collagen, and blood vessels support the tumor. The granulosa cell neoplasm must be distinguished from focal granulosa cell hyperplasia and from focal granulosa cell nodules arising in a tubular adenoma. Malignant granulosa cell tumors are quite large and present as palpable abdominal masses with increased cellular pleomorphism (polyhedral or spindle form), a high mitotic index, necrosis, and hemorrhage. Invasion and metastases are rare.

Thecoma (Figures 13-16)

Thecomas can be large and are circumscribed but non-encapsulated. Densely packed fusiform cells in whorled patterns are characteristic, giving the tumor a nodular appearance. The cytoplasm may contain lipid-laden vacuoles but this is not a dominant feature. Collagen is mainly between bundles of cells rather than around individual cells so that a silver stain for reticulin would differentiate the thecoma from a fibroma. Malignant thecomas are characterized by cellular pleomorphism, multiple areas of necrosis, mitotic figures, and invasion of the periovarian tissue.

Luteoma (Figures 17-19)
(Synonyms: Leydig cell tumor, lipid cell tumor)

Luteomas consist of large, round to polyhedral cells that resemble luteinized cells. They contain abundant eosinophilic or vacuolated cytoplasm with round to oval nuclei without much stippling.

Sertoli's Cell Tumor (Figures 20-22)

Sertoli's cell tumor occurs unilaterally as a solid, encapsulated, white/yellow, lobulated mass with occasional cysts. Over half of these tumors arise near the hilus and compress adjacent structures. It has a thin, fibrous capsule and resembles its testicular counterpart's seminiferous tubules separated by fibrovascular stroma. It has a characteristic tubular pattern of elongated tumor cells arranged perpendicular to the tubular basement membrane. The cells have basal nuclei and abundant, lightly eosinophilic, vacuolated cytoplasm. Malignancy is diagnosed when the capsule is disrupted and/or there is implantation on the peritoneal surfaces.

Sertoliform tubular adenoma

Sertoliform tubular adenomas are well-circumscribed, pale tan/white nodules or masses that range from 2–10 mm in diameter. They replace ovarian tissue and may or may not cause compression. Irregular tubules of pale, vacuolated cells with indistinct cell boundaries may give a syncytial appearance. Tumor cells often have round, intracytoplasmic, hyalin-like inclusions. Sertoliform tubular adenoma differs from the Sertoli's cell tumor in that the tubular cells lack basal nuclei and vertically oriented cytoplasm. This tumor is seen more commonly in Sprague-Dawley rats than in other strains. This tumor was previously classified with the epithelial tumors described as tubular adenomas.

OVARIAN NEOPLASMS OF GERM CELL ORIGIN

Teratoma

(Synonyms: benign teratoma, benign cystic teratoma, dermoid cyst, mature teratoma, adult teratoma, malignant teratoma, immature teratoma)

Teratomas are tumors containing any combination of well-differentiated ectodermal, mesodermal, and endodermal elements. Benign or mature tumors are predominantly cystic but may be solid. Foci of white bone or cartilage on the cut surface may be present. Microscopically, the cysts are lined by epithelium that may be cuboidal, enteric, respiratory, or keratinized squamous in nature. Mucin, keratin, or hair may be seen within the cyst. Mature nervous tissue and gastrointestinal elements are common, but a number of other tissues can often be discerned, such as muscle, hair follicles, cartilage, and bone. Usually, teratomas of the ovary are benign. The occasional malignant version has poor differentiation and most commonly is composed of neural tissue. Neural rosettes may be seen.

Yolk Sac Carcinoma (Figures 23-25)

(Synonyms: endodermal sinus tumor, yolk sac tumor)

Grossly, yolk sac carcinomas are unilateral, dark, gelatinous or cystic masses that have been observed to be up to 2.5 cm in diameter. Cystic spaces within the tumor contain serosanguineous fluid. Microscopically, there are nests, ribbons, or individual cells embedded in an abundant, eosinophilic, PAS-positive matrix. The cells are round to oval with single, central or polar, sharply defined, basophilic nuclei. The cells have distinct boundaries and are mostly of uniform size, although a few binucleated cells, giant cells, or trophoblasts have been noted. Areas of necrosis can be encountered and metastasis by local invasion or vascular channels can occur.

Choriocarcinoma (Figures 26-29)

(Synonym: chorionepithelioma)

Choriocarcinomas are described at necropsy as dark or hemorrhagic, cystic ovarian masses. Microscopically, the tumors are composed of hematocysts, hemorrhage, cytotrophoblasts, syncytiotrophoblasts, and/or trophoblastic giant cells. Cytotrophoblasts are rounded with centrally located, hyperchromatic or vesicular nuclei that are 5-10 microns in diameter.

Syncytiotrophoblasts are distinctly outlined, multinucleated cells with granular, basophilic cytoplasm. Giant cells are large, irregular cells with abundant cytoplasm and single, large nuclei up to 50 microns in diameter. Most choriocarcinomas are found in young animals and are associated with early fatality (1, 2).

MISCELLANEOUS NEOPLASMS OF THE OVARY

Fibroma/Fibrosarcoma (Figures 30 & 31)

Some difficulty may arise in morphologically distinguishing between fibromas/fibrosarcomas and thecomas. However, collagen fiber deposition can be used as a feature for differentiating fibromas/fibrosarcomas from thecomas (See description of thecoma).

Fibromas of the ovary are well-differentiated tumors consisting of fibroblasts and collagen. Collagen fibers are usually around individual fibroblasts unlike in thecomas where collagen is interspersed between bundles of tumor cells.

Hemangioma/Hemangiosarcoma

Hemangiomas/hemangiosarcomas consist of both capillaries and cavernous vascular channels which contain erythrocytes and are lined by large, plump endothelial cells.

Metastatic/Systemic Tumors (Figure 32)

Systemic tumors of the rat ovary are rare. One study reported involvement of rat ovaries in generalized abdominal mesothelioma and one case of a pancreatic adenocarcinoma that had spread throughout the abdominal cavity (16). Lymphoblastic lymphomas and large granular

lymphocyte lymphoma (LGL, Mononuclear cell leukemia or Fischer rat leukemia) may secondarily involve ovaries, as well as numerous other organs. Histiocytic sarcoma may involve the ovaries in the rat (30). The neoplastic histiocytes typically contain a dark, basophilic nucleus and abundant, distinctly eosinophilic cytoplasm.

DISCUSSION

Ovarian tumors are divided into three major categories, which are named according to their presumed histogenesis and directions of differentiation: epithelial tumors, sex cord-stromal tumors, and germ cell tumors. The morphology of the majority of rodent and human ovarian tumors is similar; however, morphologic counterparts do not always exist (2).

Granulosa cell tumors are the most common sex cord-stromal tumors in F344 rats. They are uncommon, although they do occur, in Sprague-Dawley rats (2, 16). In the Fischer 344 rat, these tumors are mostly benign althought malignant tumors do occur.

Cystadenomas/cystadenocarcinomas are generally uncommon spontaneous tumors in the rat, accounting for 1-4% of the primary ovarian tumors in F344 rats (1, 2) and 2% or less in Sprague-Dawley rats (11, 16). Cystadenocarcinomas are more common than cystadenomas.

Tubulostromal tumors are rare in F344 rats (1, 2).

Hyperplasia of the sex cord-stromal cells is quite common in old Wistar rats and probably other strains of rats but tends not to be diagnosed by some pathologists because it is viewed as a normal aging change. It is seen most commonly in 2-year carcinogenicity studies.

Teratomas of the rat ovary have only recently been reported in the literature as a result of the development of the genetically susceptible Tera strain (21). This hereditary feature appears to be due to an autosomal recessive trait that results in ovarian or testicular teratomas in about 25% of either sex. The teratomas have been described as containing tridermic tissues such as bone, epithelium, and neural tissues. Spontaneous (non-hereditary) benign and malignant teratomas of the rat ovary have been reported in an old untreated Wistar rat and a Donryu rat, respectively (18).

Spontaneous ovarian yolk sac carcinoma has been reported in the rat, but not as frequently reported as that in the mouse ovary (1). The yolk sac carcinoma of the rat differs from the yolk sac tumor of humans because the rodent yolk sac is composed of visceral and parietal layers. The parietal yolk sac lies on a thick basement membrane (Reichert's membrane) which it secretes.

Spontaneous ovarian choriocarcinoma has been reported only once in the rat (1).

Fibromas and fibrosarcomas are rare in the rat ovary. Only two fibromas and no fibrosarcomas were reported out of a total of 204 ovarian tumors from 39,851 female F344 rats from the National Toxicology Program (1, 2). A study on a wide variety of ovarian neoplasms in 5,903 aged Sprague-Dawley rats reported no fibromas or fibrosarcomas (11). In a follow-up study, neither of the tumors were reported among the 210 spontaneous ovarian tumors from 7,748 Sprague-Dawley rats (16).

Vascular tumors of the ovaries are even more rare in rats than fibromas/fibrosarcomas.

Ovarian dysgerminomas in the rat have not been reported (4). Occasional cases have been reported in other species (5, 20, 33). The marked resemblance of this tumor to the classical testicular seminoma is reflected in the synonym—ovarian seminoma.

RECOMMENDED NOMENCLATURE AND DIAGNOSTIC CRITERIA FOR NEOPLASMS AND NON-NEOPLASTIC PROLIFERATIVE LESIONS OF THE OVARY IN RATS

OVARIAN NEOPLASMS OF EPITHELIAL ORIGIN

Cystadenoma/Cystadenocarcinoma

1. Cystadenomas are single or multiple cysts lined by cuboidal or columnar epithelium with infoldings that form papillary structures
2. Usually unilateral and range from microscopic to over a centimeter in diameter
3. Single or multiple fronds protruding from the cyst wall into the lumen
4. Differential diagnoses: cystic papillary hyperplasia and mesothelioma
5. Cystadenocarcinomas are large cystic masses. Criteria of malignancy are focal atypia and/or local invasion

Tubulostromal Adenoma/Tubulostromal Carcinoma

1. Vary from microscopic to several centimeters in diameter and are frequently bilateral
2. Criteria for differentiating adenoma from epithelial hyperplasia include: a distinct mass of tubulostromal elements, compression of the adjacent tissue, and a diameter of at least 2-3 mm.
3. Consist of tubules lined by cuboidal epithelium resembling ovarian surface epithelium. Tubules are continuous with downgrowths of the surface epithelium in some areas
4. Variable ratio of tubular to non-tubular components and degree of tubular dilation
5. Tubules may be interspersed between packets of variably vacuolated or luteinized cells of probable sex cord origin. Sex cord component is variable and may form a major component of the tumor

which may lead to primary diagnosis being the sex cord component
6. Diagnosis of malignancy based upon metastasis, local invasion, and/or high mitotic index. Few or numerous cysts with blood or thrombi may be present

Mesothelioma
1. Composed of cuboidal to columnar epithelium in a papillary or frond-like pattern on the surface of the ovary or within the bursa
2. Resemble mesotheliomas in other sites of the body
3. Malignant tumors resemble adenocarcinomas, but have a frond-like pattern on the surface of the ovary and within cysts in the primary mass

NEOPLASMS AND NON-NEOPLASTIC PROLIFERATIVE LESIONS OF OVARIAN SEX CORD-STROMAL ORIGIN

Hyperplasia
1. Characterized by focal or diffuse increase in granulosa, luteal, or thecal cells as pure or mixed populations
2. May occur in atrophic ovaries and have little evidence of compression
3. Sometimes ovaries can be marginally enlarged with a diffuse, bilateral, hyperplastic change
4. Differentiated from tumors of the sex cord-stromal cells by size. Focal lesions up to 2-3 mm are considered hyperplastic, and larger lesions are considered tumors. When change is diffuse and bilateral, a 2- to 3-fold increase in ovary size is used to shift a diagnosis of hyperplasia to neoplasia

Granulosa Cell Tumor
1. Variety of histologic patterns - solid, cystic, microfollicular, sertoliform, and tubular
2. Tumor cells characteristically resemble normal granulosa cells with round to oval nuclei and coarsely stippled chromatin. Cytoplasm is variable depending upon the degree of luteinization
3. Stroma may be composed of varying amounts of theca cells, fibroblasts, collagen, and blood vessels
4. Distinguished from focal granulosa cell hyperplasia and from focal granulosa cell nodules arising in tubular adenoma by compression and size
5. Malignant granulosa cell tumor characterized by cellular pleomorphism, high mitotic index, necrosis, invasion, and metastasis

Thecoma
1. Microscopic to grossly evident masses
2. Densely packed fusiform cells usually in whorled patterns giving a nodular appearance
3. Areas of vacuolated cells may be present
4. Circumscribed but non-encapsulated

Luteoma
1. Circumscribed masses consisting mainly of large polygonal cells resembling luteinized cells
2. Tumor cells have abundant eosinophilic or vacuolated cytoplasm

Sertoli's Cell Tumor
1. Characteristic tubular pattern of elongated tumor cells arranged perpendicular to the tubular basement membrane
2. Tumor cells have basal nuclei and abundant, lightly eosinophilic, vacuolated cytoplasm
3. Thin fibrous capsule
4. Arise near hilus and compress adjacent structures
5. Malignant tumors disrupt the ovarian capsule and/or implant on peritoneal surfaces

Sertoliform Tubular Adenoma
1. Grossly, pale/white nodules or masses, 2–10 mm in diameter
2. Usually well-circumscribed and demarcated from remaining ovarian tissue; may or may not have compression
3. Irregular tubules replacing ovarian tissue
4. Tubules composed of pale, vacuolated cells with indistinct cell boundaries giving a somewhat syncytial appearance
5. Tumor cells often contain round, intracytoplasmic, hyalin-like inclusions

OVARIAN NEOPLASMS OF GERM CELL ORIGIN

Teratoma
(Synonyms: benign teratoma, benign cystic teratoma, dermoid cyst, mature teratoma, adult teratoma, malignant teratoma, immature teratoma)
1. Benign (mature) tumors are predominantly cystic but may be solid. Well-differentiated ectodermal, mesodermal, and endodermal elements may be present
2. Mature nervous tissue and gastrointestinal structures most common within cysts; other tissues may be present
3. Malignant (immature) teratomas contain some immature elements, most often neuroectodermal. Usually solid masses with a small, cystic component; but occasionally, predominantly cystic
4. Malignancy based on extension through the ovarian bursa, hemorrhage and necrosis, and poor differentiation

Yolk Sac Carcinoma
(Synonym: endodermal sinus tumor, yolk sac tumor)
1. Unilateral, dark, gelatinous or cystic masses up to

2.5 cm in diameter. Cystic spaces contain serosanguineous fluid
2. Tumor cells embedded in an eosinophilic, PAS-positive matrix
3. Pleomorphic, round to oval tumor cells arranged singly, in nests, rows, or ribbons, or in large clusters
   Binucleated and/or giant tumor cells
4. Areas of necrosis or necrosis of individual tumor cells may be present
5. Spread by local invasion or vascular spread

Choriocarcinoma
(Synonym: chorionepithelioma)

1. Dark or hemorrhagic, grossly
2. Composed of hematocysts, sheets of cytotrophoblasts, syncytiotrophoblasts, and/or trophoblastic giant cells, with areas of hemorrhage
3. Trophoblastic giant cells resemble those in deciduomas

MISCELLANEOUS NEOPLASMS OF THE OVARY

Fibroma/Fibrosarcoma

1. Fibromas are well-differentiated consisting of fibroblasts and collagen

Hemangioma/Hemangiosarcoma

1. Consist of both capillaries and cavernous channels which contain erythrocytes; lined by large, plump endothelial cells

Metastatic/Systemic Tumors

1. Mesotheliomas, pancreatic adenocarcinoma, lymphoblastic lymphoma, large granular lymphocyte (LGL) lymphoma (Mononuclear Cell or Leukemia), and diffuse histiocytic sarcoma have been reported

MORPHOLOGY

NEOPLASMS OF THE UTERUS, VAGINA, CERVIX AND OVIDUCT

UTERINE NEOPLASMS OF EPITHELIAL ORIGIN

Endometrial Adenoma (Figures 33 & 34)

Endometrial adenomas arise from the epithelium lining the uterine mucosa or comprising the endometrial glands. Spontaneous occurrence of these tumors is rare. Grossly, these tumors form well delineated solitary masses that may compress, but not invade the surrounding endometrium or adjacent myometrium. The tumor cells within endometrial adenomas are usually well-differentiated, and usually form acinar structures within a delicate fibrous stroma, or may form papillary fronds that extend into the uterine lumen. Proliferation of decidual tissue is occasionally observed in or associated with endometrial neoplasms in F344 rats.

Endometrial Adenocarcinoma (Figures 35-37)

Endometrial adenocarcinomas are poorly circumscribed growths that usually invade the surrounding myometrium, extend into and occlude the uterine lumen or metastasize to distant sites. The neoplastic epithelial cells form solid nests, cords, papillary or acinar structures that are within or supported by a stroma. The neoplastic epithelium may be well-differentiated or may have typical characteristics of anaplasia characterized by cellular and nuclear atypia, and pleomorphism. The tumor cells may be cuboidal to columnar and are usually one, two or more cell layers thick. In some instances, the multiple cell layers may give a piling or crowding effect. The lumens of the acinar structures formed by the tumor cells may be cystic or distended and may contain accumulations of cellular debris, mixed populations of inflammatory cells, and eosinophilic secretory material. Occasionally, hyalinized areas of fibrosis are within the stroma separating tumor cells. Focal areas of necrosis and hemorrhage may also be present. Endometrial adenocarcinomas with squamous differentiation may be seen and have been termed adenoacanthomas.

Squamous Cell Carcinoma (Figures 38 & 39)

Primary squamous cell carcinoma of the uterine horns and body is rare, although squamous differentiation of neoplastic epithelia in endometrial adenocarcinomas may be observed. Primary squamous cell carcinoma of endometrial epithelial origin should be distinguished from squamous cell carcinomas arising from the vaginal or cervical epithelium.

UTERINE NEOPLASMS OF NONEPITHELIAL OR UNDETERMINED ORIGIN

Yolk Sac Carcinoma (Figures 40 & 41)

(Synonyms: endomdermal sinus tumor, yolk sac tumor)

Yolk sac carcinomas involve primarily the horns of the uterus. Many of these tumors have regions showing features characteristic of the fetal membranes, the parietal and visceral yolk sacs. Yolk sac carcinomas are characterized by rosettes, nests, rows, ribbons or large clusters of neoplastic endodermal cells that appear fairly uniform in size, but in some instances may show size variation and formation of multinucleated giant cells. These cells are in a characteristic abundant amorphous hyalinized basement membrane-like material that stains pale pink with mucicarmine stain and purplish with PAS stains and is positive

ON CANCER

was established in
anced organization
headquarters of the

ting particularly on
gens in the human
ical and chemical
on, and, through
titutions in many
cation and training

contribute to the
spects of cancer
Information about
via the Internet at:

WORLD HEALTH ORGANIZATION

INTERNATIONAL AGENCY FOR RESEARCH ON CANCER

International Classification of Rodent Tumours

Part I — The Rat

8. Male Genital System

Editor-in-Chief: U. MOHR

IARC Scientific Publications No. 122

International Agency for Research on Cancer
Lyon
1997

. 42
. 43
. 45
. 46
. 49

FOREWORD

Much research has aimed at discovering *in vitro* tests for carcinogenicity of chemicals, so as to reduce the time and expense entailed by conventional animal testing, as well as to clarify to what extent results using high doses in rodents are relevant to the situation where humans are exposed to low levels of drugs, food chemicals and pollutants. However, no adequate substitute has yet been found that provides a better correlation of experimental results with epidemiological data on human carcinogenicity and therefore regulatory authorities worldwide still depend greatly upon long-term animal test results. To improve the reliability of interpretation of such results, a standardized nomenclature for the lesions observed in the tests is essential. To generate the classification presented here, scientists from both academia and industry in many countries have closely cooperated to arrive at a consensus on the descriptions of all the types of tumour and pre-neoplastic lesion encountered in laboratory work, and we believe this will lead to a significant enhancement in the quality of decision-making with respect to human exposure to toxic substances.

Updating the classification of tumours in experimental animals will also receive attention in basic cancer research. Neoplasms are now increasingly induced in transgenic animals harbouring specific oncogenes, mutated tumour-suppressor genes or combinations thereof. In addition, a variety of tumours may develop in animals which have been deprived of growth-controlling gene products by homologous recombination. A comparison with spontaneously occurring neoplasms and those induced by exposure to chemicals is becoming an increasing challenge of pathologists.

IARC is pleased to present this Classification of Rodent Tumours, which it is hoped will overcome some of the traditional inter-pathologist variability in diagnosis that has confused much past work.

We are grateful to the International Life Sciences Institute (ILSI) for its generous support for the preparation and printing of this series of fascicles. Based in Washington, D.C. (U.S.A.), ILSI aims to promote the resolution of health and safety issues and has helped to fund numerous related scientific publications.

Dr Ulrich Mohr
Director
Institute of Experimental Pathology
Hannover Medical School

Dr Paul Kleihues
Director
IARC

INTRODUCTION

Tumours and pre-neoplastic lesions of rodents have been described in many text-books and publications. The idea of this series of fascicles comprising an International Classification of Rodent Tumours is not to duplicate other excellent publications, but rather to provide information and guidelines especially adapted for international use in *practical* toxicologic pathology. This is in particular expressed in the concise easy-to-use format of the narrative in all sections. Included in this classification are tumours and relevant pre-neoplastic lesions of the rat for all organ systems. Hyperplastic and metaplastic changes are only considered in so far as they are known to be clearly pre-neoplastic, i.e., incidentally and pathogenetically associated with corresponding tumours. Other reactive hyperplastic lesions, which, for example, develop secondarily to inflammation, are not included. Furthermore, only lesions are considered for which histopathological slides are available or which have been documented with pictures in the literature.

The goal of this classification is to harmonize and standardize the nomenclature and diagnostic criteria to be used worldwide for regulatory purposes. The complete range of organ systems in the rat will be covered in ten fascicles, of which the "Male Genital System" is number eight.

Each fascicle is divided into different so-called *data-sheets*, each of which represents the essential information on a particular lesion. Furthermore, each data-sheet is prepared in a standard layout, always starting on a new page with a header section. On the left side of each header section, the lesion name (the "preferred term") appears followed in parenthesis by an indication of the lesion's biological behaviour, according to the following codes:

(H) hyperplastic and pre-neoplastic lesion
(B) benign tumour
(M) malignant tumour
(S) systemic tumour

If modifiers are defined for a particular lesion, they are printed in italics below the lesion name. On the right-hand side of the header, the organ in which the lesion occurs is mentioned. If the same criteria are used for a lesion at several topographical sites, all these organ names are included here. All lesion names used in the headers and in the synonym(s) and "differential diagnosis" sections are presented with the pathological disposition (like hyperplasia, tumour, adenoma, etc.) placed first, followed by terms describing a subtopography, a growth pattern, a cell type, etc., separated by commas. This ordering of words constitutes the structure of "preferred terms". Use of this terminology facilitates the identification and grouping of lesions with the same biological behaviour, especially when using a computerized pathology data system. In the text and the figure legends, the ordering of words is usually changed to the more common "speaking form"; thus if the preferred term is called "*adenoma, bronchiolo-alveolar*" this lesion is referred to in the text as "*bronchiolo-alveolar adenoma*".

The descriptions of the diagnostic features comprise only the main histopathological features of the specified lesion, in the form of a concise list. In several cases, modifiers are included for a more precise sub-classification to define a specific growth pattern (e.g., papil-

HYPERPLASIA *(H)*

PROSTATE
COAGULATING GLAND

Synonym(s): atypical hyperplasia

Histogenesis

Prostatic and coagulating gland acini/ducts (urogenital sinus).

Diagnostic Features

- Generally focal/multifocal lesion involving single or a few adjacent alveoli and occasionally excretory ducts, mostly in ventral prostatic lobe, rarely in dorsolateral lobe or the coagulating gland.
- No disturbance of normal alveolar architecture.
- Gradual transition from normal epithelium to focal hyperplastic areas or, at times, more abrupt changes.
- In transition areas occasional occurrence of tall columnar cells with hypereosinophilic cytoplasm and basally located hyperchromatic round to oval nuclei.
- Epithelial proliferation of three and more cell layers, sometimes forming papillary structures or cribriform pattern, occasionally loss of cellular polarity.
- Cellular atypia generally minimal, areas with increased cellular atypia and squamous metaplasia may be present.
- Decreased nucleus to cytoplasm ratio, mitotic figures infrequent.
- No capsule formation or compression of adjacent tissue.
- Usually not accompanied by inflammation.
- Proliferative lesion is not obliterating the acinar lumen.

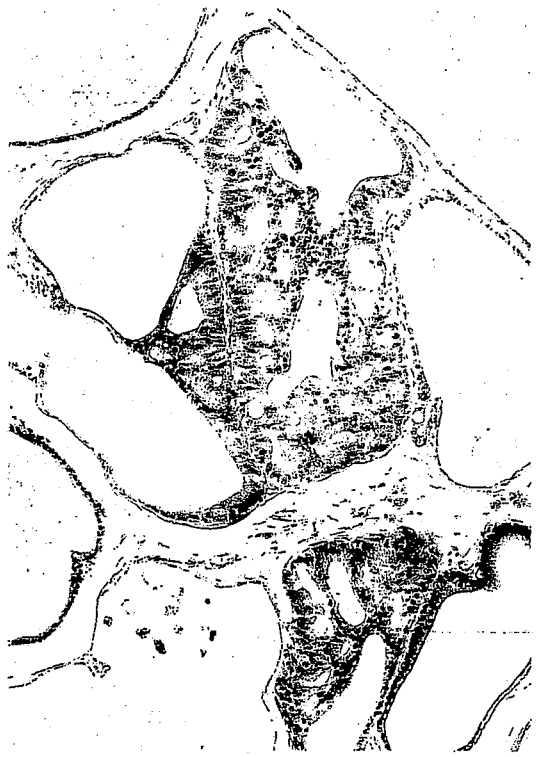

Fig. 23: Hyperplasia of the ventral prostate involving multiple adjacent acini. H&E; ×105

Differential Diagnosis

FUNCTIONAL HYPERPLASIA:

Can be diffuse or focal, usually in the periphery of the ventral prostate, 'crowded' but not truly multilayered epithelial cells of increased height and basophilia, forming folds into the alveolar lumina containing less secretion.

REACTIVE HYPERPLASIA:

Almost always combined with inflammation, most frequently found in the dorsolateral lobe, consists of a simple thickening of the epithelium to 2 – 6 or more cell layers, occasionally with pseudoglandular formation.

ADENOMA:

Distortion of normal glandular architecture and compression of adjacent tissue, comedo growth pattern frequently seen. If differentiation between focal hyperplasia and adenoma cannot be made on the basis of these criteria, a proliferative lesion obliterating one acinar lumen is interpreted to be an adenoma.

Comment

The prostate is a multilobulated organ consisting of the ventral, dorsal, lateral and dorsocranial (anterior) lobes. The latter is also referred to as coagulating gland. A macroscopic distinction of the lobes is difficult, in particular the distinction between the dorsal and lateral lobes which are often collectively referred to as dorsolateral lobe. Microscopically the peripheral and central acini of the ventral prostate differ, the peripheral ones being smaller and having more numerous epithelial infoldings, while acini of the dorsolateral lobe tend to be overall larger. The ventral prostate has only slightly eosinophilic acinar secretion, while the dorsolateral prostate has clearly eosinophilic acinar secretion.

Hyperplasia of the dorsolateral prostate is known to occur only following treatment with carcinogens usually in combination with testosterone. It differs somewhat from that of the ventral prostate: the lesion is less uniform and is characterized by small glands with a single layer of atypical cuboidal to somewhat flat cells with a hypochromatic cytoplasm and nuclei; the cellular polarity is often disturbed and no sign of secretory activity is seen; some necrosis and thickening of perialveolar fibromuscular tissue is often found.

The diagnosis of prostate/coagulating gland hyperplasia is mainly based on the occurrence of a multilayered normal epithelium in a few adjacent glands of an otherwise normal prostate without architectural disturbance.

References

See *2, 12, 30, 34, 37.*

ADENOMA *(B)*

PROSTATE
COAGULATING GLAND

Histogenesis

Prostatic and coagulating gland acini/ducts.

Diagnostic Features

- Intraalveolar epithelial proliferations partially or completely obliterating the lumina of one or more acini.
- Distortion of normal glandular architecture and compression of surrounding tissue.
- Sometimes enclosed completely or partially by a fine fibrous capsule.
- Occasionally outgrowths into adjacent alveoli/ducts (no invasion).
- Neoplastic cells predominantly arranged in cribriform pattern, rarely comedo pattern with solid and microglandular areas.
- Cells usually enlarged with round to oval hypo- or hyperchromatic nuclei, decreased nucleus to cytoplasm ratio, loss of polarity, slightly eosinophilic cytoplasm.
- Mild degree of pleomorphism, some areas of dysplasia and squamous metaplasia.
- Mitotic figures may be seen.
- Usually no inflammation with exception of some foamy macrophages.
- If differentiation between focal hyperplasia and adenoma cannot be made on the basis of criteria listed above, a proliferative lesion obliterating one acinar lumen is interpreted to be an adenoma.

Fig. 24: Adenoma of the prostate completely obliterating the lumen of one acinus. H&E; ×40

Differential Diagnosis

HYPERPLASIA:

No compression of surrounding tissue or capsule formation, generally no comedo growth pattern. Proliferative lesion is not obliterating one acinar lumen.

Fig. 25: Higher-power view of prostatic adenoma. Note cribriform pattern of neoplastic cells and numerous mitotic figures. H&E; ×210

ADENOCARCINOMA:

Invasive growth, e.g. through the capsule, and metastases, generally larger than 5 adjacent acini, often marked disruption of the architecture, central necrosis and haemorrhage sometimes found, increased cellular atypia.

Comment

The prostate is a multilobulated organ consisting of the ventral, dorsal, lateral and dorsocranial (anterior) lobes. The latter is also referred to as coagulating gland. A macroscopic distinction of the lobes is difficult, in particular the distinction between the dorsal and lateral lobes which are often collectively referred to as dorsolateral lobe. Microscopically the peripheral and central acini of the ventral prostate differ, the peripheral ones being smaller and having more numerous epithelial infoldings, while acini of the dorsolateral lobe tend to be overall larger. The ventral prostate has only slightly eosinophilic acinar secretion, while the dorsolateral prostate has clearly eosinophilic acinar secretion.

The distinction between prostate/coagulating gland hyperplasia, adenoma and carcinoma, probably representing different stages in neoplastic progression, may be arbitrary in borderline cases. Dorsolateral prostatic adenomas appear to be rare as spontaneous lesions, but have been described to be inducible chemically (Bosland, 1987). The predominant growth pattern of the induced lesion was described as microglandular to tubular; cribriform and comedo patterns were not found.

The diagnosis of a prostatic/coagulating gland adenoma is mainly based on the occurrence of acinar proliferations obliterating the lumina of generally several acini, sometimes with compression and occasionally comedo growth pattern.

References

See *1, 11, 24, 30, 34, 40.*

ADENOCARCINOMA *(M)*

PROSTATE
COAGULATING GLAND

Histogenesis

Prostatic/coagulating gland acini/ducts.

Diagnostic Features

- Mainly in the ventral prostatic lobe, generally larger than 5 alveoli, sometimes comprising the majority of the gland, often marked distortion of the architecture.
- Pleomorphic tumour cells with low nucleus to cytoplasm ratio, hyperchromatic and eosinophilic cytoplasm, large nuclei sometimes with multiple nucleoli and mitotic figures, particularly in adenocarcinomas of the dorsolateral prostate.
- Predominant growth pattern of adenocarcinomas of the ventral prostate: cribriform, comedo-type and solid; of the dorsolateral prostatic lobe and the coagulating gland: glandular/tubular structures lined by a single or occasionally double layer of epithelial cells; less well differentiated lesions with cells in solid sheets or strands.
- Haemorrhage, focal necrosis and a mixed cell inflammatory infiltrate generally seen within the tumour.
- Usually pseudolobulation by fibrous septa.
- Often with distinct fibrous capsule partly demarcating the tumour from surrounding tissue; invasive growth into adjacent alveoli and stroma may be seen, occasional metastases into regional lymph nodes, lungs and brain.

Fig. 26: Adenocarcinoma of the prostate. The tumour has a distinct cribriform pattern and invades into the capsule (top right). H&E; ×85

Differential Diagnosis

ADENOMA:

Absence of invasive growth and of widespread necrosis and disruption of architecture, only mild pleomorphism, often smaller than 5 alveoli.

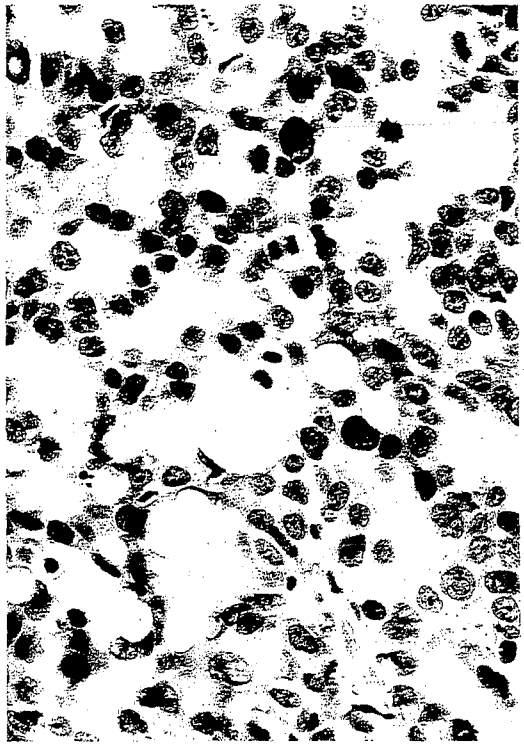

Fig. 27: Higher-power view of prostatic adenocarcinoma. Note nuclear pleomorphism and high mitotic rate. H&E; ×330

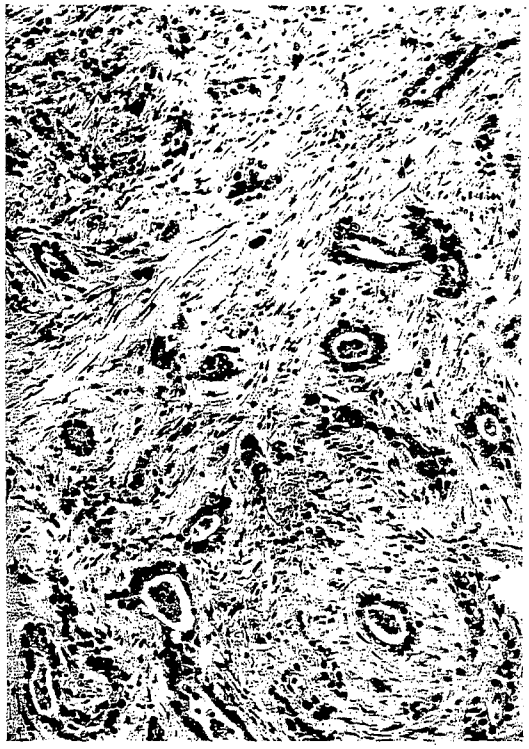

Fig. 28: Less differentiated adenocarcinoma of the prostate with abundant proliferation of stromal connective tissue. H&E; ×130

Comment

The prostate is a multilobulated organ consisting of the ventral, dorsal, lateral and dorsocranial (anterior) lobes. The latter is also referred to as coagulating gland. A macroscopic distinction of the lobes is difficult, in particular the distinction between the dorsal and lateral lobes which are often collectively referred to as dorsolateral lobe. Microscopically the peripheral and central acini of the ventral prostate differ, the peripheral ones being smaller and having more numerous epithelial infoldings, while acini of the dorsolateral lobe tend to be overall larger. The ventral prostate has only slightly eosinophilic acinar secretion, while the dorsolateral prostate has clearly eosinophilic acinar secretion.

Localization and size of tumour will generally not cause any confusion for adenocarcinomas of the ventral prostate. However, due to the highly invasive nature of scirrhous adenocarcinomas, it is frequently impossible to determine the exact gland of origin. These tumours can theoretically arise from any epithelial structure in that area, such as ampullary glands (no spontaneous tumours known), seminal vesicles, coagulating glands, ducts of these glands or the dorsolateral prostate. Urethral tumours are generally transitional cell carcinomas and thus easily distinguishable. Very large adenocarcinomas

in the pelvic cavity involving much of the cavity may have to be classified as accessory sex gland adenocarcinomas or as adenocarcinomas of unknown origin.

The diagnosis of an adenocarcinoma of the prostate/coagulating gland is mainly based on the presence of a solid and/or adenomatous invasive carcinoma with more or less widespread necrosis. Cribriform adenocarcinomas of the ventral prostate and coagulating gland may lack clear invasive growth, but are characterized by marked cellular and nuclear polymorphism.

References

See *9, 10, 19, 30, 34, 38, 40, 41.*

REFERENCES

1 Ashley DJB (1978) Evan's histological appearances of tumors. Churchill Livingstone, Edinburgh, pp 663–845

2 Bahnemann R, Jacobs M, Karbe E, Kaufmann W, Morawietz G, Nolte T, Rittinghausen S (1995) RITA – Registry of Industrial Toxicology Animal-data – Guides for organ sampling and trimming procedures in rats. *Exp Toxic Pathol* **47**: 247–266

3 Boorman GA, Abbott DP, Elwell MR, Eustis SL (1987) Sertoli's cell tumor, testis, rat. In: Jones TC, Mohr U, Hunt RD (eds) Monographs on pathology of laboratory animals. Genital system. Springer, Berlin, pp 195–199

4 Boorman GA, Chapin RE, Mitsumori K (1990) Testis and epididymis. In: Boorman GA, Eustis SL, Elwell MR, Montgomery CA, Jr, MacKenzie WF (eds) Pathology of the Fischer rat. Reference and atlas. Academic Press, San Diego New York London, pp 405–418

5 Boorman GA, Eustis SL, Elwell MR (1990) Neoplasms of the testis. In: Stinson SF, Schuller HM, Reznik GK (eds) Atlas of tumor pathology of the Fischer rat. CRC Press, Boca Raton, pp 409–414

6 Boorman GA, Eustis SL, Elwell MR (1990) Neoplasms of the testis. In: Stinson SF, Schuller HM, Reznik GK (eds) Atlas of tumor pathology of the Fischer rat. CRC Press, Boca Raton, pp 415–418

7 Boorman GA, Hamlin MH, Eustis SL (1987) Focal interstitial cell hyperplasia, testes, rat. In: Jones TC, Mohr U, Hunt RD (eds) Monographs on pathology of laboratory animals. Genital system. Springer, Berlin Heidelberg New York Tokyo, pp 200–204

8 Boorman GA, Rehm S, Waalkes MP, Elwell MR, Eustis SL (1987) Seminoma, testis, rat. In: Jones TC, Mohr U, Hunt RD (eds) Monographs on pathology of laboratory animals. Genital system. Springer, Berlin Heidelberg New York Tokyo, pp 192–195

9 Bosland MC (1987) Adenocarcinoma, seminal vesicle/coagulating gland, rat. In: Jones TC, Mohr U, Hunt RD (eds) Monographs on pathology of laboratory animals. Genital system. Springer, Berlin Heidelberg New York Tokyo, pp 272–275

10 Bosland MC (1987) Adenocarcinoma, prostate, rat. In: Jones TC, Mohr U, Hunt RD (eds) Monographs on pathology of laboratory animals. Genital system. Springer, Berlin Heidelberg New York Tokyo, pp 252–260

11 Bosland MC (1987) Adenoma, prostate, rat. In: Jones TC, Mohr U, Hunt RD (eds) Monographs on pathology of laboratory animals. Genital system. Springer, Berlin Heidelberg New York Tokyo, pp 261–266

12 Bosland MC (1987) Hyperplasia, prostate, rat. In: Jones TC, Mohr U, Hunt RD (eds) Monographs on pathology of laboratory animals. Genital system. Springer, Berlin Heidelberg New York Tokyo, pp 267–272

13 Chandra M, Riley MGI (1994) Rarely occurring spontaneous metastasizing testicular tumors in rats. Histopathologic and ultrastructural features. *Exp Toxic Pathol* **46**: 155–161

14 Ettlin RA, Qureshi SR, Perentes E, Christen H, Gschwind R, Buser MW, Oberholzer M (1992) Morphological, immunohistochemical, stereological and nuclear shape characteristics of proliferative Leydig cell alterations in rats. *Path Res Pract* **188**: 643–648

15 Honma K, Yamada T (1984) Zur Bedeutung der 'Kapselinfiltration' der testikulären Leydigzellen – eine Obduktionsstudie. *Zbl allg Pathol u pathol Anat* **129**: 403–411

16 Kanno J, Matsuoka C, Furuta K, Onodera H, Maekawa A, Hayashi Y (1987) Glandular changes associated with the spontaneous interstitial cell tumor of the rat testes. *Toxicol Pathol* **15**: 439–443

17 Kim SN, Fitzgerald JE, De La Iglesia FA (1985) Spermatocytic seminoma in the rat. *Toxicol Pathol* **15:** 215–221

18 Kojima A, Yamashita K, Tsutsui K, Ishii S (1984) Development of 'granulosa' cell tumors from intrasplenic testicular transplants in castrated Aci rats. *Gann* **75:** 159–165

19 Lee CH, Holland JM (1987) Anatomy, histology, and ultrastructure, prostate, rat. In: Jones TC, Mohr U, Hunt RD (eds) Monographs on pathology of laboratoray animals. Genital system. Springer, Berlin Heidelberg New York Tokyo, pp 239–251

20 Maekawa A, Hayashi Y (1987) Adenomatous hyperplasia, rete testis, rat. In: Jones TC, Mohr U, Hunt RD (eds) Monographs on pathology of laboratory animals. Genital system. Springer, Berlin Heidelberg New York Tokyo, pp 234–236

21 Maekawa A, Hayashi Y (1992) Neoplastic lesions of the testis. In: Mohr U, Dungworth DL, Capen CC (eds) Pathobiology of the aging rat. Vol I. ILSI Press, Washington, pp 413–418

22 McConnell RF, Westen HH, Ulland BM, Bosland MC, Ward JM (1992) Proliferative lesions of the testes in rats with selected examples from mice, URG-3. In: Guides for toxicologic pathology. STP/ARP/AFIP, Washington

23 Mitsumori K, Elwell MR (1988) Proliferative lesions in the male reproductive system of F344 rats and B6C3F1 mice: Incidence and classification. *Environ Health Perspect* **77:** 11–21

24 Mostofi FK, Bresler VM (1976) Tumours of the testis. In: Turusov VS (ed) Pathology of tumours in laboratory animals. Vol I. Tumours of the rat, Part 2. IARC Scientific Publications No. 6, Lyon, pp 135–153

25 Nielsen SW, Misdorp W, McEntee K (1976) Tumours of the ovary. *Bull WHO* **53:** 203–215

26 Qureshi SR, Perentes E, Ettlin RA, Kolopp M, Prentice DE, Frankfurter A (1991) Morphologic and immunohistochemical characterization of Leydig cell tumor variants in Wistar rats. *Toxicol Pathol* **19:** 280–286

27 Rao MS, Reddy JK (1987) Interstitial cell tumor, testis, rat. In: Jones TC, Mohr U, Hunt RD (eds) Monographs on pathology of laboratory animals. Genital system. Springer, Berlin Heidelberg New York Tokyo, pp 184–192

28 Rehm S, Dierksen D, Deerberg F (1984) Spontaneous ovarian tumors in Han:NMRI mice: Histologic classification, incidence, and influence of food restriction. *J Natl Cancer Inst* **72:** 1383–1395

29 Rehm S, Waalkes MP (1988) Mixed Sertoli-Leydig cell tumor and rete testis adenocarcinoma in rats treated with $CdCl_2$. *Vet Pathol* **25:** 163–166

30 Reznik G, Hamlin MH, Ward JM, Stinson SF (1981) Prostatic hyperplasia and neoplasia in aging F344 rats. *Prostate* **2:** 261–268

31 Reznik G, Reznik-Schüller H (1980) Pathology of the clitoral and preputial glands in aging F344 rats. *Lab Anim Sci* **30:** 845–850

32 Reznik G, Ward JM (1981) Morphology of hyperplastic and neoplastic lesions in the clitoral and preputial gland of the F344 rat. *Vet Pathol* **18:** 228–238

33 Reznik G, Ward JM (1981) Morphology of neoplastic lesions in the clitoral and prepucial gland of the F344 rat. *J Cancer Res Clin Oncol* **101:** 249–263

34 Reznik GK (1990) Prostatic hyperplasia and neoplasia. In: Stinson SF, Schuller HM, Reznik GK (eds). Atlas of tumor pathology of the Fischer rat. CRC Press, Boca Raton, pp 419–429

35 Serov SF, Scully RE, Sobin LH (1973) International histological classification of tumours No 9. Histological typing of ovarian tumours. WHO, Geneva, pp 1–56

36 Serov SF, Scully RE, Sobin LH (1973) International histological classification of tumours No 9. Histological typing of ovarian tumours. WHO, Geneva, pp 1–56

37 Shirai T, Imaida K, Masui T, Iwasaki S, Mori T, Kato T, Ito N (1994) Effects of testosterone, dihydrotestosterone and estrogen on 3,2'-dimethyl-4-aminobiphenyl-induced rat prostate carcinogenesis. Int J *Cancer* **57**: 224–228

38 Slayter MV, Anzano MA, Kadomatsu K, Smith JM, Sporn MB (1994) Histogenesis of induced prostate and seminal vesicle carcinoma in Lobund-Wistar rats: a system for histological scoring and grading. *Cancer Res* **54**: 1140–1145

39 Sobis H (1987) Teratoma, uterus, rat. In: Jones TC, Mohr U, Hunt RD (eds) Monographs on pathology of laboratory animals. Genital system. Springer, Berlin Heidelberg New York Tokyo, pp 120–126

40 Squire RA, Goodman DG, Valerio MG, Fredrickson T, Strandberg JD, Levitt MH, Lingeman CH, Harshbarger JC, Dawe CJ (1978) Tumors. Male reproductive system. In: Benirschke K, Garner FM, Jones TC (eds) Pathology of laboratory animals Vol II. Springer, Berlin, pp 1213–1225

41 Ward JM, Reznik G, Stinson SF, Lattuada CP, Longfellow DG, Cameron TP (1980) Histogenesis and morphology of naturally occurring prostatic carcinoma in the ACI/sep HapBR rat. *Lab Invest* **43**: 517–522

CANCER

established in
d organization
quarters of the

particularly on
s in the human
and chemical
and, through
tions in many
on and training

ribute to the
cts of cancer
ormation about
the Internet at:

WORLD HEALTH ORGANIZATION

INTERNATIONAL AGENCY FOR RESEARCH ON CANCER

International Classification of Rodent Tumours

Part I — The Rat

9. Female Genital System

Editor-in-Chief: U. MOHR

IARC Scientific Publications No. 122

International Agency for Research on Cancer
Lyon
1997

FOREWORD

Much research has aimed at discovering *in vitro* tests for carcinogenicity of chemicals, so as to reduce the time and expense entailed by conventional animal testing, as well as to clarify to what extent results using high doses in rodents are relevant to the situation where humans are exposed to low levels of drugs, food chemicals and pollutants. However, no adequate substitute has yet been found that provides a better correlation of experimental results with epidemiological data on human carcinogenicity and therefore regulatory authorities worldwide still depend greatly upon long-term animal test results. To improve the reliability of interpretation of such results, a standardized nomenclature for the lesions observed in the tests is essential. To generate the classification presented here, scientists from both academia and industry in many countries have closely cooperated to arrive at a consensus on the descriptions of all the types of tumour and pre-neoplastic lesion encountered in laboratory work, and we believe this will lead to a significant enhancement in the quality of decision-making with respect to human exposure to toxic substances.

Updating the classification of tumours in experimental animals will also receive attention in basic cancer research. Neoplasms are now increasingly induced in transgenic animals harbouring specific oncogenes, mutated tumour-suppressor genes or combinations thereof. In addition, a variety of tumours may develop in animals which have been deprived of growth-controlling gene products by homologous recombination. A comparison with spontaneously occurring neoplasms and those induced by exposure to chemicals is becoming an increasing challenge of pathologists.

IARC is pleased to present this Classification of Rodent Tumours, which it is hoped will overcome some of the traditional inter-pathologist variability in diagnosis that has confused much past work.

We are grateful to the International Life Sciences Institute (ILSI) for its generous support for the preparation and printing of this series of fascicles. Based in Washington, D.C. (U.S.A.), ILSI aims to promote the resolution of health and safety issues and has helped to fund numerous related scientific publications.

Dr Ulrich Mohr
Director
Institute of Experimental Pathology
Hannover Medical School

Dr Paul Kleihues
Director
IARC

CONTRIBUTORS

Dr R. Alison
Quay Fields
Snave
Bantry Cork
Ireland

Dr R.A. Ettlin*
Sandoz Tsukuba Research Institute
Ohkubo 8
300-33 Tsukuba-shi, Ibaraki
Japan

Dr G.L. Foley
University of Illinois
Department of Pathobiology
College of Veterinary Medicine
2001 S. Lincoln Avenue
Urbana, IL 61801
USA

Dr J.H. Harleman*
ASTA Medica AG
Institute of Toxicology
Kantstrasse 2
D-33790 Halle/West.
Federal Republic of Germany

Dr A. Maekawa
Department of Pathology
Sasaki Institute
2-2, Kanda Surugadai
Chiyoda-ku
Tokyo 101
Japan

Dr R.F. McConnell**
12 Cherryville-Stanton Road
Flemington, NJ 08822
USA

Dr S.R. Qureshi*
Sandoz AG
Drug Safety Assessment
Toxicology
CH-4002 Basel
Switzerland

Dr S. Rehm
SmithKline Beecham
Toxicology
709 Swedeland Road
King of Prussia, PA 19406
USA

Dr G. Reznik*
BYK Gulden Pharmazeutika
Institut für Pathologie und Toxikologie
Friedrich-Ebert-Damm 101
D-22047 Hamburg
Federal Republic of Germany

Dr M. Valerio
Rorer Central Research
800 Business Center Drive, 5A
Horsham, PA 19044
USA

*Dr Robert Ettlin, Dr Hans Harleman, Dr Shafqat Qureshi and Dr Gerd Reznik prepared the initial draft of this document.

**Chairman of the working group.

INTRODUCTION

Tumours and pre-neoplastic lesions of rodents have been described in many text-books and publications. The idea of this series of fascicles comprising an International Classification of Rodent Tumours is not to duplicate other excellent publications, but rather to provide information and guidelines especially adapted for international use in *practical* toxicologic pathology. This is in particular expressed in the concise easy-to-use format of the narrative in all sections. Included in this classification are tumours and relevant pre-neoplastic lesions of the rat for all organ systems. Hyperplastic and metaplastic changes are only considered in so far as they are known to be clearly pre-neoplastic, i.e., incidentally and pathogenetically associated with corresponding tumours. Other reactive hyperplastic lesions, which, for example, develop secondarily to inflammation, are not included. Furthermore, only lesions are considered for which histopathological slides are available or which have been documented with pictures in the literature.

The goal of this classification is to harmonize and standardize the nomenclature and diagnostic criteria to be used worldwide for regulatory purposes. The complete range of organ systems in the rat will be covered in ten fascicles, of which the "Female Genital System" is number nine.

Each fascicle is divided into different so-called *data-sheets*, each of which represents the essential information on a particular lesion. Furthermore, each data-sheet is prepared in a standard layout, always starting on a new page with a header section. On the left side of each header section, the lesion name (the "preferred term") appears followed in parenthesis by an indication of the lesion's biological behaviour, according to the following codes:

(H) hyperplastic and pre-neoplastic lesion
(B) benign tumour
(M) malignant tumour
(S) systemic tumour

If modifiers are defined for a particular lesion, they are printed in italics below the lesion name. On the right-hand side of the header, the organ in which the lesion occurs is mentioned. If the same criteria are used for a lesion at several topographical sites, all these organ names are included here. All lesion names used in the headers and in the synonym(s) and "differential diagnosis" sections are presented with the pathological disposition (like hyperplasia, tumour, adenoma, etc.) placed first, followed by terms describing a subtopography, a growth pattern, a cell type, etc., separated by commas. This ordering of words constitutes the structure of "preferred terms". Use of this terminology facilitates the identification and grouping of lesions with the same biological behaviour, especially when using a computerized pathology data system. In the text and the figure legends, the ordering of words is usually changed to the more common "speaking form"; thus if the preferred term is called "*adenoma, bronchiolo-alveolar*" this lesion is referred to in the text as "*bronchiolo-alveolar adenoma*".

The descriptions of the diagnostic features comprise only the main histopathological features of the specified lesion, in the form of a concise list. In several cases, modifiers are included for a more precise sub-classification to define a specific growth pattern (e.g., papil-

lary, solid, cystic, etc.) or to sub-divide findings by cell type (e.g., phaeochromocytoma type, small cell type, etc.). The criteria which are specific for modifiers are listed under subheadings. Because illustrations are essential in pathology, most lesions are documented with at least one micrograph. These illustrations have been selected from among both spontaneous or induced lesions.

The section "differential diagnosis" is also kept as short as possible and includes only the main diagnostic criteria used in distinguishing lesions. In the (literature) reference section of each data-sheet only numbers are printed which refer to the numbered list of references at the end of the fascicle. Only the most recently published and important papers are included in the literature references.

An "electronic" version of this classification with a more extensive range of colored illustrations will be issued once the series of fascicles is complete. This will enhance the speed and facility of access to the information required for accurate diagnosis.

History

The basic outline of this classification was prepared by pathologists in chemical and pharmaceutical companies from Germany and Switzerland and at the Fraunhofer Institute of Toxicology and Aerosol Research in Hannover, Germany. The initial goal was to define nomenclature and diagnostic criteria for use in the *Registry of Industrial Toxicology Animal-data – RITA*. This data base of spontaneously occurring tumours and pre-neoplastic lesions observed in control rats of long-term carcinogenicity and chronic toxicity studies was set up in 1988 and is continuously expanding, already containing data from thousands of control rats.

In order to be able to store in a central data base findings derived from different laboratories and different pathologists, and to be able to reliably compare and evaluate the results, it was realized that the use of a systematized nomenclature and precisely defined diagnostic criteria was essential.

In the late 1980s, the Society of Toxicologic Pathology, in the USA, also started an initiative to standardize diagnostic criteria of neoplastic and pre-neoplastic lesions in the rat and further similar efforts are being undertaken in Japan. In order to try to harmonize these different endeavours, IARC has brought together scientists from many countries to generate this series of publications, that it hopes will become a standard for toxicologic pathology. An Editorial Board for the project as a whole, as well as individual Reviewer Panels for each organ system, enable all points of view to be taken into consideration, in order to encourage international acceptance of this system of standardized nomenclature and harmonized diagnostic criteria.

U. Mohr (FRG) D.L. Dungworth (USA) N. Ito (Japan)
C.C. Capen (USA) R.A. Griesemer (USA) V.S. Turusov (Russia)

The Editorial Board thanks Dr H. Ernst for preparing some of the illustrations and Dipl.-Ing. G. Morawietz for establishing the structure of the nomenclature, suitable for electronic data processing, for preparing the proofs for the fascicle and for the technical editing in collaboration with Dr J. Cheney.

view of cystadenocar-
papillary structures.

HYPERPLASIA, SEX CORD STROMAL *(H)* OVARY

Granulosa cell
Theca cell
Sertoli cell
Mixed type
Diffuse mixed type

Histogenesis

Sex cord/stromal cells.

Diagnostic Features

- Lesion may show variable morphological spectrum including granulosa cells, theca cells, Sertoli cells, luteal cells, etc., often in varying quantities.
- Quite common, in old rats two distinct lesions can be distinguished.

Focal:

- Focal lesions are discrete lesions, which are well demarcated from the adjacent tissue.
- Lesions show often predominance (> 70%) of one cell type, i.e. granulosa, theca, or Sertoli. Mixed lesions are ones in which more than one cell type is present.
- Diameter does not exceed the size of a corpus luteum.

Diffuse mixed type (old age type):

- May be present multifocally or diffusely throughout the ovary and involve the entire ovary.
- Poorly demarcated lesions showing a mixture of stromal and sex cord cells. Cell types most frequently associated with this type of lesion are Sertoli-type cells and stromal cells. The Sertoli-type cells have a clear cytoplasm and are arranged in cords or strands, occasionally in tubules.

Fig. 12: Focal granulosa cell hyperplasia. This lesion is well circumscribed and smaller than a corpus luteum. H&E; ×40

- Diameter is smaller than or equal to the size of a normal ovary.

Fig. 13: Higher-power view of granulosa cell hyperplasia showing uniform population of granulosa cells. H&E; ×210

Fig. 14: Diffuse mixed type of sex cord stromal hyperplasia, high grade. H&E; ×40

Differential Diagnosis

TUMOUR, SEX CORD STROMAL, MIXED, BENIGN:

Differentiation between hyperplasia and sex cord stromal tumours is arbitrary and difficult.

Sex cord stromal tumours are distinct masses, which may compress the adjacent tissues. Hyperplasia, especially of the diffuse mixed type, tends to have a gradual transition with the adjacent tissues.

Focal discrete lesions larger than a large corpus luteum are, in the absence of any other morphological criteria, such as atypia, pleomorphism, high mitotic rate and invasiveness, considered to be a tumour.

Diffuse mixed-type lesions occasionally become very large. They may encompass the major part of the ovary and have a size larger than a normal ovary. In these cases they are arbitrarily registered as tumour, sex cord stromal, benign, mixed type.

TUMOUR, GRANULOSA CELL, BENIGN or TUMOUR, SERTOLI CELL, BENIGN or THECOMA, BENIGN:

Discrete nodule and/or compression and/or diameter of proliferative lesion is larger than the size of a corpus luteum. One cell type predominates.

:ed type of sex cord stro-
;h grade. H&E; ×40

, considered to be a tu-

ɔe lesions occasionally be-
They may encompass the
ıe ovary and have a size
·mal ovary. In these cases
:ily registered as tumour,
, benign, mixed type.

ULOSA CELL, BENIGN
ɛTOLI CELL, BENIGN
ɜNIGN:

.e and/or compression
: of proliferative lesion is
size of a corpus luteum.
edominates.

Fig. 15: Higher-power view of diffuse mixed type of sex cord stromal hyperplasia showing the mixed cellular characteristics of this lesion with Sertoliform tubules. H&E; ×85

Comment

The diffuse mixed type (old age type) hyperplasia is common in old rats.

References

See *4, 23, 24, 29.*

TUMOUR, GRANULOSA CELL, BENIGN *(B)* OVARY

Synonym(s): tumour, sex cord stromal, benign, granulosa cell type

Histogenesis

Sex cord/stromal cells.

Diagnostic Features

- Cellular morphology resembles that of normal granulosa cells.
- Nuclei round to oval with coarsely stippled chromatin.
- Cytoplasm varies from scanty to moderate depending upon degree of luteinization and is faintly eosinophilic and vacuolated.
- Several patterns such as follicular, solid and trabecular identified.
- Some large tumours contain areas of haemorrhage and necrosis with lipofuscin granules.
- Occasionally, larger granulosa cell tumours show areas or are partially composed of fusiform theca-like cells. The predominant component, however, is the granulosa cell.
- Diameter of proliferative lesion is larger than the size of a corpus luteum.

Differential Diagnosis

HYPERPLASIA, SEX CORD STROMAL (GRANULOSA CELL), focal:

No distinct compression and/or displacement of surrounding tissue. In the absence of other morphological characteristics: lesions of predominantly one cell type smaller than or equal to a large corpus luteum should be called a hyperplasia and larger than that a tumour.

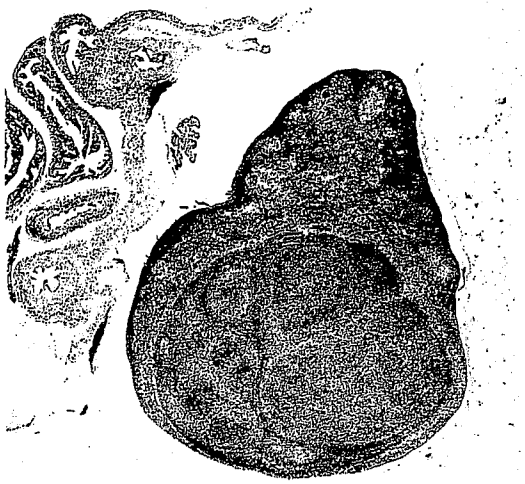

Fig. 16: Benign granulosa cell tumour showing a well demarcated nodule. H&E; ×15

TUMOUR, GRANULOSA CELL, MALIGNANT:

The distinction between benign and malignant granulosa cell tumour is made on the degree of atypia, infiltrative growth pattern, presence of metastasis, and areas of necrosis and haemorrhage indicative of a high growth rate.

OVARY

ulosa cell tumour show-
d nodule. H&E; ×15

LOSA CELL,

tween benign and malig-
l tumour is made on the
infiltrative growth pat-
metastasis, and areas of
norrhage indicative of a

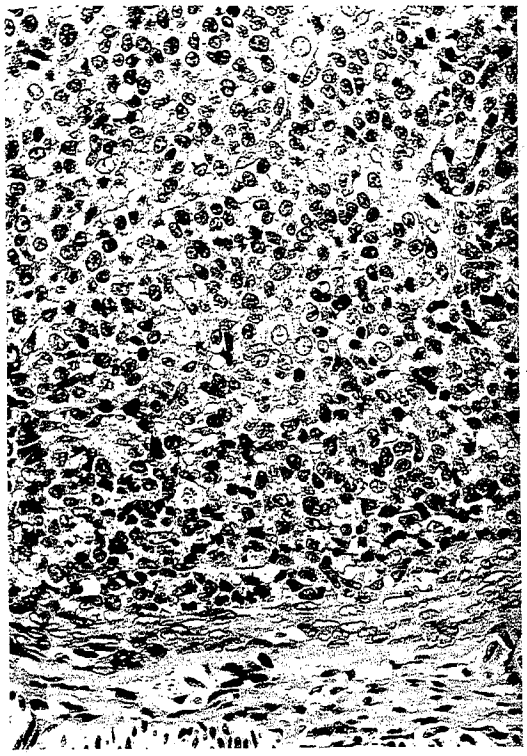

Fig. 17: Higher-power view of benign granulosa cell tumour showing a uniform population of granulosa cells and sharply demarcated border. H&E; ×330

LUTEOMA, BENIGN or THECOMA, BENIGN or TUMOUR, SERTOLI CELL, BENIGN:

Differentiation from luteoma, thecoma, Sertoli cell tumour is based upon the predominant characteristics of the tumour. In the case of granulosa cell tumours, the granulosa cell type should be predominant.

Comment

Granulosa cell tumours are the most common ovarian tumours in Fischer F344 and Sprague-Dawley rats.

References

See *1, 3, 4, 16, 23, 26.*

TUMOUR, GRANULOSA CELL, MALIGNANT *(M)*

OVARY

Synonym(s): gynoblastoma; tumour, sex cord stromal, malignant, granulosa cell type

Histogenesis

Sex cord/stromal cells.

Diagnostic Features

- Malignant granulosa cell tumours have evidence of local invasion, a high degree of cellular pleomorphism and a high mitotic rate.
- Focal areas of necrosis and haemorrhage are frequently present.
- Tumour may show distant metastases to kidneys, lungs, and lymph nodes.
- Cellular morphology resembles that of normal granulosa cells.
- Nuclei round to oval with coarsely stippled chromatin.
- Cytoplasm varies from scanty to moderate depending upon degree of luteinization and is faintly eosinophilic and vacuolated.
- Several patterns such as follicular, solid and trabecular identified.
- Occasionally, granulosa cell tumours show areas or are partially composed of fusiform theca-like cells.

Fig. 18: Malignant granulosa cell tumour with necrosis and invasion into the adjacent tissues. H&E; ×15

Differential Diagnosis

TUMOUR, GRANULOSA CELL, BENIGN:

The distinction between benign and malignant granulosa cell tumour is based on the degree of atypia, infiltrative growth pattern, presence of metastasis, and areas of necrosis and haemorrhage indicative of a high growth rate.

LUTEOMA, BENIGN or THECOMA, MALIGNANT or TUMOUR, SERTOLI CELL, MALIGNANT:

Differentiation from luteoma, thecoma, Sertoli cell tumour is based upon the predominant cell type present. In the case of

OVARY

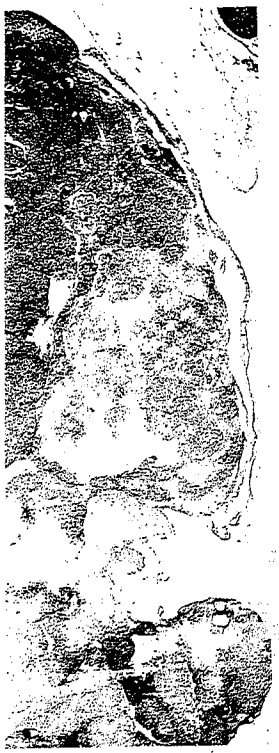

granulosa cell tumour
asion into the adjacent

orrhage indicative of a

N or THECOMA,
JMOUR, SERTOLI
T:

om luteoma, thecoma,
is based upon the pre-
present. In the case of

Fig. 19: Malignant granulosa cell tumour with focal necrosis. H&E; ×85



Fig. 20: Higher-power view of malignant granulosa cell tumour, showing invasion. H&E; ×210

granulosa cell tumours the latter cell type should be predominant.

References

See *1, 2, 3, 4, 16, 23, 26.*

THECOMA, BENIGN *(B)* OVARY

Synonym(s): tumour, sex cord stromal, benign, thecoma type; tumour, theca cell, benign

Histogenesis

Sex cord/stromal cells.

Diagnostic Features

- Composed of densely packed fusiform cells, usually arranged in interlacing bundles and whorls giving a nodular appearance.
- Variable amount of lipid and collagen present. Collagen is mainly between bundles of cells.
- Extensive necrosis in large tumours with only perivascular persistence of viable tissue.
- Focal areas of mineralization and hyalinization may be present.
- Diameter of proliferative lesion is larger than the size of a corpus luteum.

Fig. 21: Benign thecoma showing a well circumscribed nodule of uniform spindle cells slightly larger than a corpus luteum. H&E; ×45

Differential Diagnosis

FIBROMA:

Fibromas lack lipid-laden cells and have collagen arranged around individual cells.

HYPERPLASIA, SEX CORD STROMAL:

Sex cord stromal hyperplasia is generally diffuse and mixed in character, but may be focal, and in the latter case does form a distinct entity, which is smaller than or equal in size to a large corpus luteum.

TUMOUR, GRANULOSA CELL, BENIGN or LUTEOMA, BENIGN:

Differentiation between thecomas and the other sex cord stromal tumours is based on the predominant cell type present. In thecoma the major cell type is spindle-shaped theca cell.

OVARY



coma showing a well cir-
of uniform spindle cells
a corpus luteum. H&E;

ULOSA CELL, BENIGN
ENIGN:

between thecomas and the
romal tumours is based on
cell type present. In the-
cell type is spindle-shaped

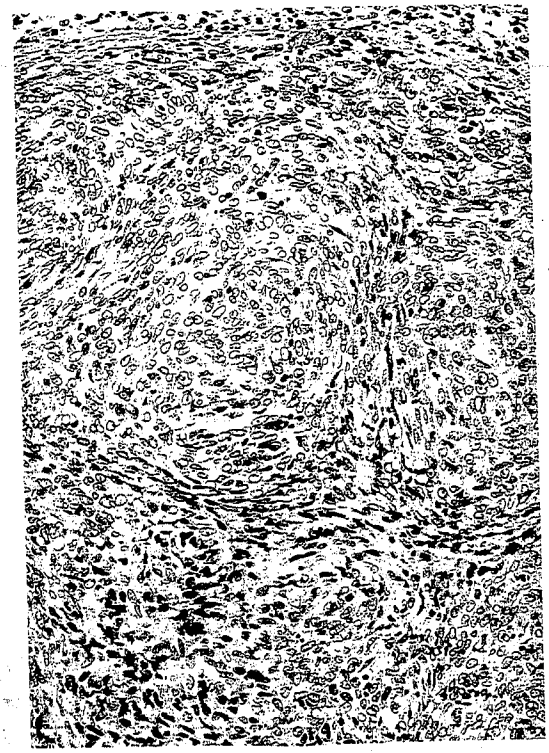

Fig. 22: Higher-power view of benign thecoma with a uniform population of fusiform cells. H&E; ×210

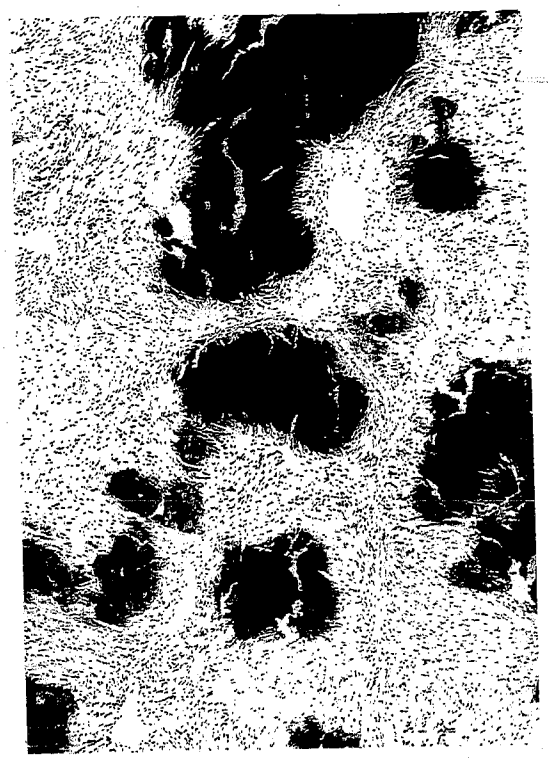

Fig. 23: Benign thecoma showing marked multifocal mineralization. H&E; ×85

THECOMA, MALIGNANT:

Differentiation between benign and malignant thecoma is based on the presence of an infiltrative growth pattern, an invasion of the adjacent tissue, degree of atypia, and metastasis in the malignant thecoma.

References

See *1, 3, 4, 16, 23, 26.*

THECOMA, MALIGNANT *(M)*

OVARY

Synonym(s): tumour, sex cord stromal, malignant, thecoma type; tumour, theca cell, malignant

Histogenesis

Sex cord/stromal cells.

Diagnostic Features

- Composed of densely packed fusiform cells, usually arranged in whorls giving a nodular appearance.
- Spindle-shaped cells arranged in interlacing bundles and whorled patterns.
- Variable amount of lipid and collagen present. Collagen arranged between bundles of cells.
- Extensive necrosis in large tumours with only perivascular persistence of viable tissue.
- Focal areas of mineralization and hyalinization may occur.
- Malignant thecomas also show pleomorphism and multiple areas of necrosis suggesting rapid growth, infiltration of adjacent tissue and/or metastasis.

Fig. 24: Malignant thecoma with invasion into the adjacent tissues. H&E; ×35

Differential Diagnosis

FIBROMA or FIBROSARCOMA:

Fibromas or fibrosarcomas lack lipid-laden cells and have collagen arranged around individual cells.

TUMOUR, GRANULOSA CELL, MALIGNANT or LUTEOMA, BENIGN:

Differentiation between thecomas and the other sex cord stromal tumours is based on the predominant cell type present. In the case of thecoma the major cell type is spindle-shaped theca cell.

THECOMA, BENIGN:

Differentiation between benign and malignant thecoma is based on the presence of an infiltrative growth pattern, the degree of atypia, invasion of the adjacent tissue, and metastasis in the malignant thecoma.

OVARY

.nt thecoma with invasion
:issues. H&E; ×35

.nant cell type present. In
:oma the major cell type is
theca cell.

VIGN:

between benign and malig-
is based on the presence of
growth pattern, the degree
sion of the adjacent tissue,
in the malignant thecoma.

Fig. 25: Higher-power view of malignant thecoma with mitosis. H&E; ×330

References

See *3, 4, 16, 23, 26, 39.*

LUTEOMA, BENIGN *(B)* OVARY

Synonym(s): gonadal stromal sex cord tumour, benign, luteoma type; luteinized granulosa cell tumour, benign

Histogenesis

Sex cord/stromal cells.

Diagnostic Features

- Composed of highly luteinized cells with abundant pale granular cytoplasm with distinct cell boundaries. Nuclei are round to oval without significant stippling.
- Intranuclear cytoplasmic invaginations and mast cells occasionally present.
- Tumour generally shows a slight degree of cellular pleomorphism.
- Connective tissue may divide the tumour into small lobules compared to normal corpus luteum.
- Diameter of proliferative lesion is larger than that of three corpora lutea.

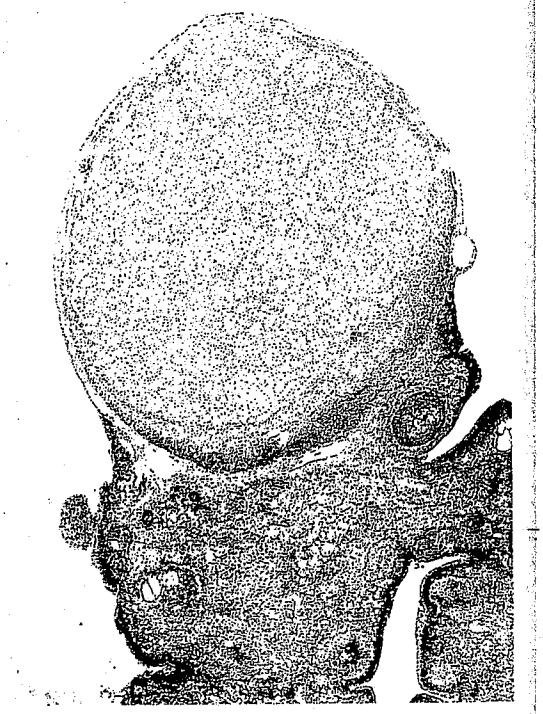

Fig. 26: Benign luteoma showing a well circumscribed nodule of highly luteinized cells. H&E; ×35

Differential Diagnosis

TUMOUR, GRANULOSA CELL, BENIGN or THECOMA, BENIGN:

Differentiation between luteomas and other sex cord stromal tumours is based upon the predominant cell type present. Granulosa cell tumours and thecomas do not have such a high degree of luteinization.

Comment

Luteoma, malignant has not been reported. Nuclear atypia or pleomorphism does not imply malignancy. Luteinized cells sometimes occur in malignant and benign granulosa cell tumours.

References

See *1, 4, 16, 23, 26.*

OVARY

:oma showing a well cir-
ıf highly luteinized cells.

ınd benign granulosa cell

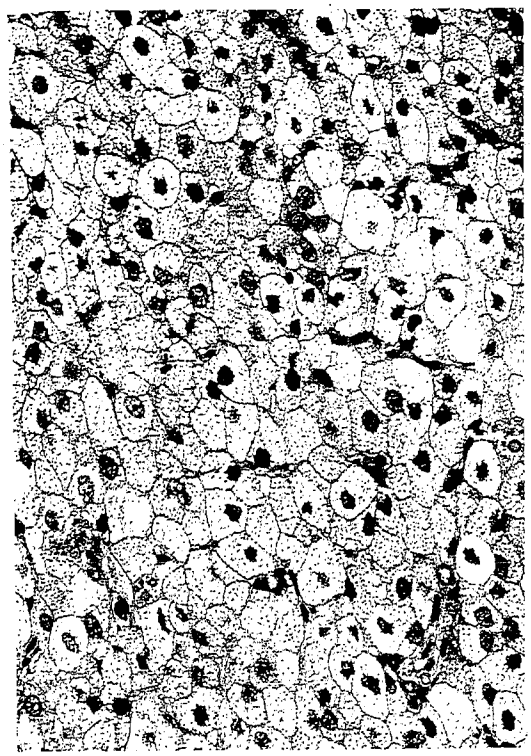

Fig. 27: Higher-power view of benign luteoma with well differentiated highly luteinized and finely vacuolated cytoplasm and centrally located nucleus. H&E; ×330

TUMOUR, SERTOLI CELL, BENIGN *(B)* OVARY
Tubular

Synonym(s): tumour, gonadal stromal, benign; tumour, sex cord stromal, benign; tumour, sex cord stromal, benign, Sertoli type; tumour, sustentacular, benign

Histogenesis

Sex cord/stromal cells.

Diagnostic Features

- Sertoli cell tumours resemble their testicular counterpart.
- Characterized by seminiferous-like tubules separated by fibrovascular stroma, lined by cells with basally located nuclei and abundant faintly eosinophilic cytoplasm extending into the lumen.
- No spermatogenic cells seen.
- These tumours frequently have areas with nests of vacuolated cells/Sertoli cells without obvious tubular structures.
- These tumours have frequently a relatively high proportion of fusiform theca-like cells.
- If differentiation between focal hyperplasia and benign sertoli cell tumour cannot be based on the basis of criteria listed above, a proliferative lesion with a diameter larger than the size of a corpus luteum is interpreted to be a tumour.

Differential Diagnosis

HYPERPLASIA, SEX CORD STROMAL (SERTOLI CELL):

Diameter is smaller than or equal to the size of a corpus luteum.

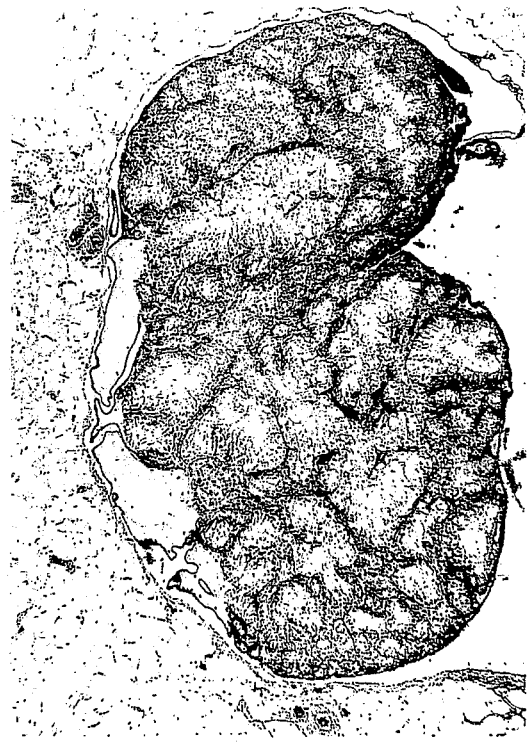

Fig. 28: Benign Sertoli cell tumour showing circumscribed nodule with tubular structures. H&E; ×40

TUMOUR, GRANULOSA CELL, BENIGN or THECOMA, BENIGN:

Sertoli tumours are differentiated from granulosa cell tumours and other sex cord stromal tumours by their tubular growth pattern and cellular characteristics (predominant cell type present).

OVARY

ertoli cell tumour show-
odule with tubular struc-

ULOSA CELL, BENIGN
NIGN:

are differentiated from
mours and other sex cord
s by their tubular growth
lular characteristics (pre-
pe present).

Fig. 29: Benign Sertoli cell tumour showing seminiferous like tubules. H&E; ×85

TUMOUR, SERTOLI CELL, MALIGNANT:

The malignant Sertoli cell tumour is differentiated from the benign Sertoli cell tumour by more poorly differentiation, infiltrative growth pattern and areas of haemorrhage and necrosis.

Comment

This category includes Sertoliform tubular adenomas. In Sprague-Dawley strains a tubular form exists with irregular tubules made up of pale vacuolated cells with indistinct cell boundaries which may give a syncytial appearance. These cells often have intracytoplasmic hyalin-like PAS-positive inclusions. This variant differs from the other Sertoli cell type tumour in that the tubular cells lack basal nuclei and vertically oriented cytoplasm.

References

See *1, 3, 4, 16, 23, 26, 39.*

TUMOUR, SERTOLI CELL, MALIGNANT *(M)* OVARY

Synonym(s): androblastoma; arrhenoblastoma; tumour, gonadal stromal, malignant; tumour, sex cord stromal, malignant; tumour, sex cord stromal, malignant, Sertoli type; tumour, sustentacular, malignant

Histogenesis

Sex cord/stromal cells.

Diagnostic Features

- Sertoli cell tumours resemble their testicular counterpart.
- Characterized by seminiferous-like tubules separated by fibrovascular stroma, lined by cells with basally located nuclei and abundant faintly eosinophilic cytoplasm extending into the lumen.
- No spermatogenic cells seen.
- Malignancy is evidenced on the basis of focal necrosis, haemorrhage, and local invasion and/or metastasis.
- Malignant Sertoli cell tumours are usually less well differentiated, exhibiting rounded pleomorphic cells.
- Areas of granulosa-like cells may be present but are not the main characteristic.

Differential Diagnosis

TUMOUR, GRANULOSA CELL, MALIGNANT or THECOMA, MALIGNANT:

Sertoli tumours are differentiated from granulosa cell tumour and other sex cord stromal tumours by their tubular growth pattern and cellular characteristics.

Fig. 30: Malignant Sertoli cell tumour showing nests and tubular structures. H&E; ×210

TUMOUR, SERTOLI CELL, BENIGN:

The malignant Sertoli cell tumour is differentiated from the benign Sertoli cell tumour by more poorly differentiated infiltrative growth pattern and areas of haemorrhage and necrosis.

References

See *1, 3, 4, 16, 23, 26, 30, 36, 39.*

OVARY

ertoli cell tumour show-
r structures. H&E; ×210

LI CELL, BENIGN:

ertoli cell tumour is dif-
he benign Sertoli cell tu-
oorly differentiated infil-
ttern and areas of haem-
osis.

26, 30, 36, 39.

TUMOUR, SEX CORD STROMAL, MIXED, BENIGN *(B)*

OVARY

Histogenesis

Sex cord/stromal cells.

Diagnostic Features

- Tumour consists of a mixture of granulosa, luteal, theca, Sertoli and stromal cells, which may show various degrees of differentiation. No cell type dominates (> 70%).
- Discrete well demarcated focal lesions, which are bigger than one large corpus luteum.
- Included in this category are also extremely large diffuse mixed-type lesions which encompass the whole ovary and are in size/diameter markedly larger than a normal ovary (old age type sex cord stromal hyperplasia).

Differential Diagnosis

TUMOUR, GRANULOSA CELL, BENIGN or TUMOUR, SERTOLI CELL, BENIGN or THECOMA, BENIGN or TUMOUR, GRANULOSA CELL, MALIGNANT or TUMOUR, SERTOLI CELL, MALIGNANT or THECOMA, MALIGNANT:

One differentiated cell type dominates (Sertoli, granulosa, theca) (> 70 %).

HYPERPLASIA, SEX CORD STROMAL (FOCAL):

Little or no compression. Diameter is smaller than or equal to that of a corpus luteum. Discrete lesion with clear demarcation and generally of one cell type, e.g. granulosa or theca.

Fig. 31: Benign mixed sex cord stromal tumour showing large nodule with a mixed morphological character. H&E; ×35

HYPERPLASIA, SEX CORD STROMAL (DIFFUSE MIXED TYPE):

Sex cord stromal diffuse mixed hyperplasia type is differentiated from sex cord stromal mixed tumour by the non-discrete growth characteristics of the diffuse mixed type. Only those lesions of the diffuse mixed type which are extremely large are included in this category. In diffuse mixed hyperplasias the size/diameter of the lesion is

Fig. 32: Higher-power view of benign mixed sex cord stromal tumour showing mixed morphological character with vacuolated cells, granulosa and fusiform cells. H&E; ×210

less than or equal to that of a normal ovary. Very large lesions markedly bigger in size and diameter than the normal ovary are included in the tumour category.

References

See *1*, *4*.

REFERENCES

1 Alison RH, Morgan KT (1987) Ovarian neoplasms in F344 rats and B6C3F1 mice. *Environ Health Perspect* **73:** 91–106

2 Alison RH, Morgan KT (1987) Teratoma, ovary, mouse. In: Jones TC, Mohr U, Hunt RD (eds) Monographs on pathology of laboratory animals. Genital system. Springer, Berlin Heidelberg New York Tokyo, pp 46–52

3 Alison RH, Morgan KT, Haseman JK, Boorman GA (1987) Morphology and classification of ovarian neoplasms in F344 rats and (C57BL/6 × C3H)F_1 mice. *J Natl Cancer Inst* **78:** 1229–1243

4 Alison RH, Morgan KT, Montgomery CA (1990) Ovary. In: Boorman GA, Eustis SL, Elwell MR, Montgomery CA, Jr, MacKenzie WF (eds) Pathology of the Fischer rat. Reference and atlas. Academic Press, San Diego New York London, pp 429–442

5 Anisimov VN, Nikonov AA (1990) Tumours of the vagina, uterus and oviduct. In: Turusov VS, Mohr U (eds) Pathology of tumours in laboratory animals. Vol I. Tumours of the rat, 2nd edition. IARC Scientific Publications No. 99, Lyon, pp 445–471

6 Ashley DJB (1990) Evan's histological appearances of tumors. Churchill Livingstone, Edinburgh, pp 773–861

7 Campbell JS (1987) Adenoacanthoma, uterus, rat. In: Jones TC, Mohr U, Hunt RD (eds) Monographs on pathology of laboratory animals. Genital system. Springer, Berlin Heidelberg New York Tokyo, pp 110–115

8 Ernst H, German PG, Rittinghausen S, Mohr U (1990) Mesodermale (Muellersche) Mischtumoren des Uterus bei der Ratte. *Berl Münch Tierärztl Wochenschr* **103:** 431

9 Goodman DG, Hildebrandt PK (1987) Adenocarcinoma, endometrium, rat. In: Jones TC, Mohr U, Hunt RD (eds) Monographs on pathology of laboratory animals. Genital system. Springer, Berlin Heidelberg New York Tokyo, pp 80–82

10 Goodman DG, Hildebrandt PK (1987) Papillary adenoma, endometrium, rat. In: Jones TC, Mohr U, Hunt RD (eds) Monographs on pathology of laboratory animals. Genital system. Springer, Berlin Heidelberg New York Tokyo, pp 78–80

11 Goodman DG, Hildebrandt PK (1987) Squamous cell carcinoma, endometrium/cervix, rat. In: Jones TC, Mohr U, Hunt RD (eds) Monographs on pathology of laboratory animals. Genital system. Springer, Berlin Heidelberg New York Tokyo, pp 82–83

12 Goodman DG, Hildebrandt PK (1987) Stromal polyp, endometrium, rat. In: Jones TC, Mohr U, Hunt RD (eds) Monographs on pathology of laboratory animals. Genital system. Springer, Berlin Heidelberg New York Tokyo, pp 146–148

13 Goodman DG, Hildebrandt PK (1987) Stromal sarcoma, endometrium, rat. In: Jones TC, Mohr U, Hunt RD (eds) Monographs on pathology of laboratory animals. Genital system. Springer, Berlin Heidelberg New York Tokyo, pp 70–72

14 Gopinath C, Prentice DE, Lewis DJ (1987) Atlas of experimental toxicological pathology. MTP Press, Lancaster Boston The Hague Dordrecht, pp 94–97

15 Greaves P, Faccini JM (1984) Rat histopathology. A glossary for use in toxicity and carcinogenicity studies. Elsevier, Amsterdam New York Oxford, pp 173–175

16 Gregson RL, Lewis DJ, Abbott DP (1984) Spontaneous ovarian neoplasms of the laboratory rat. *Vet Pathol* **21:** 292–299

17 Hart-Elcock L, Stuart BP, Mueller RE, Hoss HE (1987) Deciduoma, uterus, rat. In: Jones TC, Mohr U, Hunt RD (eds) Monographs on pathology of laboratory animals. Genital system. Springer, Berlin Heidelberg New York Tokyo, pp 140–146

18 Johnson LD (1978) Lesions of the female genital system caused by diethylstilbestrol in humans, subhuman primates, mice. In: Jones TC, Mohr U, Hunt RD (eds) Monographs on pathology of laboratory animals. Genital system. Springer, Berlin Heidelberg New York Tokyo, pp 84–109

19 Jones TC, Hunt RD (1983) Veterinary pathology. Lea & Febiger, Philadelphia, pp 1524–1525

20 Kaspareit-Rittinghausen J, Deerberg F (1990) Spontaneous malignant mixed müllerian tumors and rhabdomyosarcoma of the uterus in rats. *Toxicol Pathol* **18:** 417–422

21 Leininger JR, Jokinen MP (1990) Oviduct, uterus and vagina. In: Boorman GA, Eustis SL, Elwell MR, Montgomery CA, Jr, MacKenzie WF (eds) Pathology of the Fischer rat. Reference and atlas. Academic Press, San Diego New York London, pp 443–459

22 Lemon PG, Gubareva AV (1979) Tumours of the ovary. In: Turusov VS (ed) Pathology of tumours in laboratory animals. Vol. II. Tumours of the mouse. IARC Scientific Publications No. 23, Lyon, pp 385–409

23 Lewis DJ (1987) Ovarian neoplasia in the Sprague-Dawley rat. *Environ Health Perspect* **73:** 77–90

24 MacLachlan NJ (1987) Ovarian disorders in domestic animals. *Environ Health Perspect* **73:** 27–33

25 Maekawa A (1990) Tumours of the ovary. In: Turusov VS, Mohr U (eds) Pathology of tumours in laboratory animals. Vol I. Tumours of the rat, 2nd edition. IARC Scientific Publications No. 99, Lyon, pp 473–497

26 Maekawa A, Hayashi Y (1987) Granulosa/theca cell tumor, ovary, rat. In: Jones TC, Mohr U, Hunt RD (eds) Monographs on pathology of laboratory animals. Genital system. Springer, Berlin Heidelberg New York Tokyo, pp 15–22

27 Majeed SK, Alison RH, Boorman GA, Gopinath C (1986) Ovarian yolk sac carcinoma in mice. *Vet Pathol* **23:** 776–778

28 Mitsuhashi N, Takahashi T, Nozaki M, Matsumoto H, Sakurai H, Takahashi M, Niibe H (1993) Establishment and characterization of a rat yolk sac tumor cell line, NMT-1, producing α-fetoprotein, with potential for lymphatic metastasis. *Jpn J Cancer Res* **84:** 1287–1291

29 Montgomery CA, Alison RH (1987) Nonneoplastic lesion of the ovary in Fischer 344 rats and B6C3F1 mice. *Environ Health Perspect* **73:** 53–75

30 Morgan KT, Alison RH (1987) Tubular adenoma, ovary, mouse. In: Jones TC, Mohr U, Hunt RD (eds) Monographs on pathology of laboratory animals. Genital system. Springer, Berlin Heidelberg New York Tokyo, pp 36–41

31 Nielsen SW, Misdorp W, McEntee K (1976) Tumours of the ovary. *Bull WHO* **53:** 203–215

32 Nyska A, Klein T, Scolnik M, Waner T, Klein B (1994) Unusually high incidence of spontaneous endometrial adenocarcinoma in aged virgin Fischer rats. *Exp Toxic Pathol* **46:** 7–9

33 Reznik G, Reznik-Schüller H (1980) Pathology of the clitoral and preputial glands in aging F344 rats. *Lab Anim Sci* **30:** 845–850

34 Reznik G, Ward JM (1981) Morphology of hyperplastic and neoplastic lesions in the clitoral and preputial gland of the F344 rat. *Vet Pathol* **18:** 228–238

35 Reznik G, Ward JM (1981) Morphology of neoplastic lesions in the clitoral and prepucial gland of the F344 rat. *J Cancer Res Clin Oncol* **101:** 249–263

36 Serov SF, Scully RE, Sobin LH (1973) International histological classification of tumours No 9. Histological typing of ovarian tumours. WHO, Geneva, pp 1–56

37 Sobis H (1987) Choriocarcinoma, uterus, rat. In: Jones TC, Mohr U, Hunt RD (eds) Monographs on pathology of laboratory animals. Genital system. Springer, Berlin Heidelberg New York Tokyo, pp 138–140

38 Sobis H (1987) Yolk sac carcinoma, rat. In: Jones TC, Mohr U, Hunt RD (eds) Monographs on pathology of laboratory animals. Genital system. Springer, Berlin Heidelberg New York Tokyo, pp 127–134

39 Stoica G, Capen CC, Koestner A (1987) Sertoli's cell tumor, ovary, rat. In: Jones TC, Mohr U, Hunt RD (eds) Monographs on pathology of laboratory animals. Genital system. Springer, Berlin Heidelberg New York Tokyo, pp 30–36

40 Vollmer G, Deerberg F, Siegal GP, Knuppen R (1991) Altered tenascin expression during spontaneous endometrial carcinogenesis in the BDII/Han rat. *Virchows Arch B* **60:** 83–89

Laboratory Animal & Molecular Pathology

TOXICOLOGIC PATHOLOGY, vol 29, no 4, pp 467–478, 2001
Copyright © 2001 by the Society of Toxicologic Pathology

A Retrospective Analysis of Background Lesions and Tissue Accountability for Male Accessory Sex Organs in Fischer-344 Rats

TAKAHIKO SUWA,[1] ABRAHAM NYSKA,[1] JOHN C. PECKHAM,[3] JAMES R. HAILEY,[1] JOEL F. MAHLER,[1] JOSEPH K. HASEMAN,[2] AND ROBERT R. MARONPOT[1]

[1]*Laboratory of Experimental Pathology,*
[2]*Biostatistics Branch, National Institute of Environmental Health Sciences, Research Triangle Park, North Carolina 27709, and*
[3]*Experimental Pathology Laboratories Inc., Research Triangle Park, North Carolina 27709*

ABSTRACT

Because the paired lobes (ventral, dorsal, lateral, and anterior) of the rat prostate have not been consistently sampled in many carcinogenicity and toxicity studies, comparison among different investigations has been compromised. The lack of specific site identification for prostatic lesions further lessens the value of incidences reported. We present here the lobe-specific incidences and degree of severity of background prostatic, seminal vesicular, and ampullary glandular lesions in 1768 control Fischer-344 rats from 35 recent National Toxicology Program 2-year carcinogenicity and toxicity studies conducted in 4 laboratories. The dorsal and lateral lobes were combined and considered the dorsolateral lobe where inflammation, epithelial degeneration, mucinous cysts, and edema were observed. Inflammation in the dorsolateral lobes was significantly associated with pituitary gland adenoma whose prolactin was suggested to play an important role in pathogenesis of prostatic inflammation. Epithelial degeneration, epithelial hyperplasia, inflammation, edema, and adenoma were conspicuous in the ventral lobes. Inflammation and edema occurred in the anterior lobes (coagulating glands). Inflammation, dilatation, epithelial hyperplasia, edema, and adenoma were observed in the seminal vesicles. Inflammation was also present in the ampullary glands. We suggest an optimal embedment and trimming method in rat prostate and seminal vesicle to ensure adequate, consistent sampling.

Keywords. Accessory male sex glands; background data; histopathology; rodents; pituitary gland adenoma; prolactin; spontaneous.

INTRODUCTION

Assessment of the potential toxicological and carcinogenic effects of a chemical compound in male accessory sex glands including prostate, seminal vesicle, and ampullary gland may be difficult if the incidence of spontaneous histopathological background lesions is unknown. Although the rat prostate has been used as an experimental model to analyze the function of androgenic hormones (26, 28), few background histopathological data exist for this gland and other male accessory sex glands in Fischer-344 (F-344) rats commonly used in 2-year carcinogenicity and toxicity studies (6, 11, 18, 41, 50).

The rat prostate consists of 4 paired lobes including ventral, dorsal, lateral, and anterior (4, 23, 27, 28). The coagulating glands, which represent the anterior lobes, are easily distinguishable from the other prostatic lobes and have been reported separately from prostate in routine studies. Most biological studies of the rat prostate have been performed on the ventral lobe because gross visualization of the dorsal and lateral lobes is difficult (28). Although the ventral, dorsal, and lateral lobes differ morphologically and functionally (19, 20, 23, 28), few studies have identified these lobes separately (12, 13, 17, 18, 33–37, 50). Because the paired lobes of the rat prostate have not always been sampled consistently in past carcinogenicity and toxicity studies, comparison among different studies has been compromised. Omission of the identification of specific sites for prostatic lesions in controls lessens the value of reported background incidences. Histopathological lesions in the seminal vesicles and ampullary glands have seldom been reported (4, 6–8, 18, 22, 30, 46, 50).

This retrospective histopathological examination was undertaken to document lobe-specific tissue accountability and incidences of background histopathological lesions in the prostate, seminal vesicles, and ampullary glands in control F-344 rats from 35 recent 2-year carcinogenicity and toxicity studies conducted in 4 laboratories for the National Toxicology Program (NTP). In addition, possible associations between various lesions were explored statistically; in particular, possible correlation between prostatic inflammation and the presence of pituitary gland adenomas was evaluated, because exposure to prolactin (PRL) has been implicated in the development of prostatitis (40, 42, 51, 52), and prolactinomas are common in F-344 rats.

Address correspondence to: Abraham Nyska, Laboratory of Experimental Pathology, National Institute of Environmental Health Sciences, PO Box 12233, Research Triangle Park, North Carolina 27709; e-mail: nyska@niehs.nih.gov.

0192-6233/01$3.00+$0.00

The method of tissue trimming is vital for accurate histopathological examination and interpretation of each lobe of the rat prostate. One sectioning method, sagittal, has been previously proposed for rat prostate (5–7). The standard operating procedure (SOP) of the NTP study, however, has been to make a single transverse section including both dorsolateral and ventral lobes of the prostate just posterior to the urinary bladder. Our survey indicated, however, that the prostate was not uniformly trimmed among the 4 laboratories performing these NTP studies. We detail a trimming and embedment guideline to ensure optimal histological sampling of the rat prostate.

METHODS

Prostate, seminal vesicle, and ampullary gland tissue sections from 1768 control male F-344 rats were obtained from selected feed (n = 20), gavage (n = 12), and drinking water (n = 3) 2-year carcinogenicity and toxicity studies conducted using the NTP's SOP. Twenty recent bioassay studies were chosen from Laboratory A, and the remaining 15 studies were selected from 3 other laboratories—B, C, and D—operating under Good Laboratory Practice guidelines. Housing conditions for the rats had been standardized according to NTP specifications (10). For each animal, a complete necropsy had been performed and included gross and histopathological examination of major organs and all gross lesions. Tissues had been fixed in 10% neutral buffered formalin, embedded in paraffin, sectioned at 4 μm, and stained with hematoxylin and eosin (H&E). Selected sections of prostate were cut from NTP blocks and stained with Masson-trichrome and Alcian blue (pH 2.5)-periodic acid Schiff (PAS).

Because distinguishing between dorsal and lateral lobes on a routine basis in carcinogenicity and toxicity studies is difficult, we combined the dorsal and lateral lobes from the NTP slides and considered them the dorsolateral lobe (4, 6, 7). Histopathological lesions were thus recorded as dorsolateral lobe, ventral lobe, coagulating gland, seminal vesicle, and ampullary gland.

The amount of tissue from dorsolateral and ventral lobes, coagulating gland, seminal vesicle, and ampullary gland was estimated subjectively as a percentage of an optimal transverse section and assigned a category: none, 1–25%, 26–50%, 51–75%, and 76–100%.

The severity of nonproliferative lesions was scored subjectively using 4 grades based on the size and/or multiplicity of the lesions expressed as the percentage of acini, as follows: (1) minimal—lesion occurring in less than 10% of acini; (2) mild—10–39%; (3) moderate—40–79%; (4) marked—more than 80%.

After documentation of lobe-specific lesions in the prostate, the incidence data for some of the common findings were evaluated statistically for the following possible associations:

a. Presence of pituitary gland adenomas with the incidence and severity of prostatic inflammation in the dorsolateral and ventral lobes,
b. Prostatic inflammation with incidence of hyperplasia in the ventral lobe,
c. Prostatic inflammation with mucinous cysts of the dorsolateral lobe.

The data from 5 recent studies conducted at Laboratory A (33–37) were utilized for this purpose because prostatic tissue accountability has been found to be optimal from this facility since 1985. Multiple and logistic regression statistical analyses (14, 49) were used after adjusting for survival differences and study-to-study variability.

For immunohistochemistry, 15 paraffin sections of pituitary gland containing adenomas were cut from randomly selected blocks from 5 recent studies (33–37) without regard to presence or absence of prostatic lesions and examined by the avidin-biotin complex (ABC) method (21) using rabbit antisera at the following dilutions as primary antibody: anti-rat prolactin (PRL), 1:400; anti-rat growth hormone (GH), 1:200; anti-rat thyroid-stimulating hormone (TSH), 1:400; anti-rat luteinizing hormone (LH), 1:200; and anti-human adrenocorticotrophic hormone (ACTH), undiluted. Rabbit anti-human ACTH was obtained from DAKO Corporation, Santa Barbara, California, and other primary antibodies were purchased from Biogenesis, Inc., Sandown, New Hampshire. The biotinylated secondary antibody and ABC complex were obtained from Vector Corporation, Burlingame, California. Then, 3, 3′-diaminobenzidine (DAB) was applied as a substrate for the peroxidase reaction, and slides were counterstained with hematoxylin.

RESULTS

The relative amounts of tissue from prostatic lobes, seminal vesicles, and ampullary glands are summarized in Table 1. The data show that the quantity of dorsolateral and ventral lobe tissue was highly variable among laboratories so that a preponderance of either dorsolateral or ventral lobe occurred depending on sampling. The quantity of these tissues varied within each individual laboratory as well, indicating inconsistency of sampling among studies. Tissues from the ventral lobe were missed altogether in Laboratories C and D in a large percentage of cases. Because more than 51% of the maximum transverse area was usually present in coagulating gland and seminal vesicle sections from each laboratory, consistent sectioning did not seem to be a problem for these tissues. Ampullary glands were found not to be sectioned in Laboratories C and D in a large percentage of cases.

Detailed criteria for defining normal histological and histopathological characteristics in prostate, coagulating glands, seminal vesicles, and ampullary glands have been reported in the literature (3, 4, 23, 28) and are described briefly next for comparison with characteristics of lesions encountered in our survey. Our own observations of lesion occurrence are noted following the summarized descriptions.

Normal Prostate

The lateral regions of the dorsolateral lobes (see Figure 1) are bound to the urethra by smooth muscle, connective tissue stroma, and ducts. The acini of the lateral lobes are large and loosely arranged within stroma and contain strongly eosinophilic secretions. The epithelium is cuboidal to columnar, and the nuclei of the epithelial cells are centrally located; supranuclear areas of cytoplasmic pallor are prominent.

The dorsal regions of the dorsolateral lobes are separated from the lateral regions by thin smooth muscle and connective tissue stroma. Secretion in the dorsal lobes is moderately eosinophilic; the acini are large, but with minimal infolding,

TABLE 1.—Quantity of tissue present.

Laboratory	A	B	C	D
Number of studies	20	5	5	5
Number of animals examined	1003	253	260	252
Dorsolateral lobe	(969)	(246)	(26)	(142)
none	34 (3.4%)	7 (2.8%)	234 (90.0%)	110 (43.7%)
1–25%	41 (4.1%)	14 (5.5%)	14 (5.4%)	26 (10.3%)
26–50%	199 (19.8%)	93 (36.8%)	5 (1.9%)	65 (25.8%)
51–75%	241 (24.0%)	55 (21.7%)	2 (0.8%)	21 (8.3%)
76–100%	488 (48.7%)	84 (33.2%)	5 (1.9%)	30 (11.9%)
Ventral lobe	(524)	(82)	(242)	(190)
none	479 (47.8%)	171 (67.6%)	18 (6.9%)	62 (24.6%)
1–25%	105 (10.5%)	65 (25.7%)	6 (2.3%)	19 (7.5%)
26–50%	104 (10.4%)	14 (5.5%)	79 (30.4%)	71 (28. 2%)
51–75%	145 (14.5%)	2 (0.8%)	79 (30.4%)	46 (18.3%)
76–100%	170 (16.9%)	1 (0.4%)	78 (30.0%)	54 (21.4%)
Coagulating gland	(850)	(202)	(212)	(224)
none	153 (15.3%)	51 (20.2%)	48 (18.5%)	28 (11.1%)
1–25%	39 (3.9%)	9 (3.6%)	8 (3.1%)	5 (2.0%)
26–50%	47 (4.7%)	13 (5.1%)	11 (4.2%)	6 (2.4%)
51–75%	93 (9.3%)	23 (9.1%)	15 (5.8%)	10 (4.0%)
76–100%	671 (66.9%)	157 (62.1%)	178 (68.5%)	203 (80.6%)
Seminal vesicle	(993)	(252)	(256)	(248)
none	10 (1.0%)	1 (0.4%)	4 (1.5%)	4 (1.6%)
1–25%	8 (0.8%)	1 (0.4%)	2 (0.8%)	1 (0.4%)
26–50%	50 (5.0%)	4 (1.6%)	9 (3.5%)	6 (2.4%)
51–75%	162 (16.2%)	9 (3.6%)	13 (5.0%)	15 (6.0%)
76–100%	773 (77.1%)	238 (94.1%)	232 (89.2%)	226 (89.7%)
Ampullary gland	(632)	(222)	(8)	(69)
none	371 (37.0%)	31 (12.3%)	25 (96.9%)	183 (72.6%)
1–25%	100 (10.0%)	20 (7.9%)	3 (1.2%)	11 (4.4%)
26–50%	82 (8.2%)	47 (18.6%)	2 (0.8%)	20 (7.9%)
51–75%	140 (14.0%)	43 (17.0%)	3 (1.2%)	18 (7.1%)
76–100%	310 (30.9%)	112 (44.3%)	0 (0.0%)	20 (7.9%)

( ): Number of animals with available tissue for evaluation.
%: Percentage of an optimum cross-section that is present.
(%): Percentage of total number of animals.

and loosely distributed within stroma. The epithelium is generally cuboidal, and the nuclei of the epithelial cells are centrally located; supranuclear areas of cytoplasmic pallor are observed.

The ventral lobes are attached to the urethra by smooth muscle, connective tissue stroma, and ducts whose epithelium is mainly cuboidal. Secretions in the acini, which were rather tightly packed in the stroma, are pale and slightly eosinophilic. The acini of the ventral lobes exhibit infrequent and varying degrees of infolding. The epithelium is columnar to cuboidal and basophilic, and the nuclei of the epithelial cells are basally located; supranuclear areas of cytoplasmic pallor are conspicuous.

Normal Coagulating Glands

The coagulating gland acini are tightly packed, surrounded by thick smooth muscle and connective tissue stroma and attached to the seminal vesicles. The acini are typically infolded and contain moderately eosinophilic secretion. The epithelium is generally columnar. The nuclei of the epithelial cells are centrally located; basilar areas of cytoplasmic pallor are prominent.

Normal Seminal Vesicles

Thick smooth muscle cells and connective tissue stroma surround the acini that are infolded peripherally and exhibit a strongly eosinophilic secretion in a centrally distended lumen. The epithelium is columnar, and the nuclei of the epithelial cells are basally located with areas of cytoplasmic pallor in the apical cytoplasm.

Normal Ampullary Glands

These glands encircle the vas deferens. The acini are large, uniform in size and surrounded by smooth muscle and connective tissue stroma. A strongly eosinophilic secretion containing clear vacuoles is typically artifactually separated from the epithelium by clear space. The epithelium is flattened to cuboidal, and the nuclei of the epithelial cells are centrally located.

The incidence of histopathological lesions in prostatic lobes, coagulating glands, seminal vesicles and ampullary glands is summarized in Table 2. Descriptions for the nonproliferative and epithelial proliferative lesions follow.

Prostatic, Coagulating Glandular, Seminal Vesicular, and Ampullary Glandular Inflammation

This lesion is characterized by various degrees of inflammatory cell infiltration both in the interstitium and acinus (Figure 2). The lumina contain neutrophilic infiltrations and include various amounts of secretion, often accompanied by accumulations of tissue debris, sometimes forming abscesses. Denudation of the epithelium often coexists with neutrophilic exudation. Reactive hyperplasia, squamous metaplasia, and vacuolar degeneration of epithelium are observed in involved acini (Figure 3). Lymphocytes and plasma cells infiltrate thickened periacinar interstitial connective tissues in varying degrees. Fibrosis as a part of inflammatory reactions is frequently observed in the interstitium.

Our observations indicated that inflammation occurred from greater to lesser frequency in, respectively, the dorsolateral lobe, ventral lobe, ampullary gland, coagulating gland, and seminal vesicle.

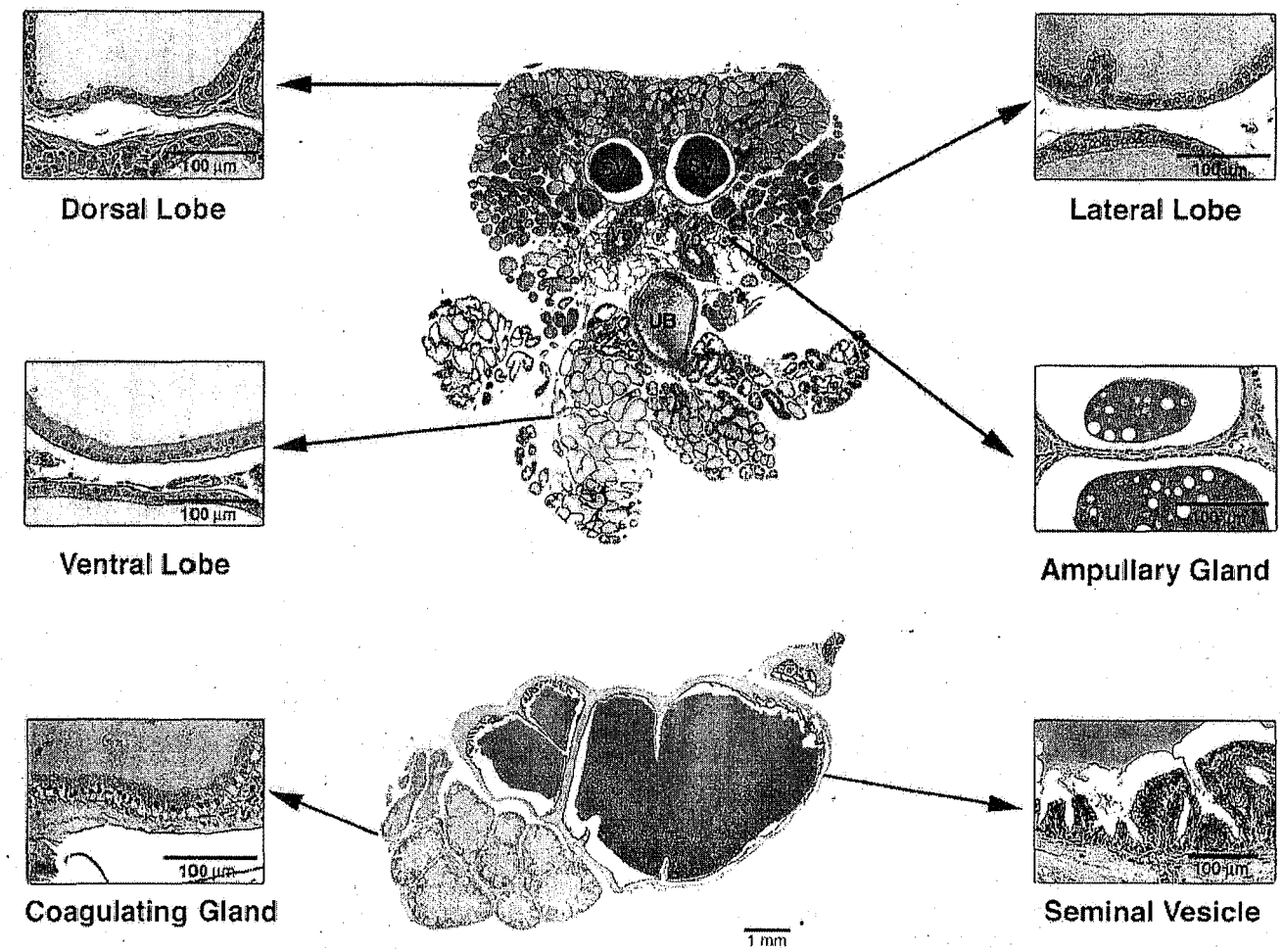

FIGURE 1.—Mid-transverse section of prostate and seminal vesicle. Prostate section consists of dorsal, lateral, and ventral lobes with portions of the seminal vesicle (SV), vas deferens (VD), and urinary bladder (UB) visible. The seminal vesicle section contains seminal vesicle and coagulating gland. H&E stain. Bars = 1 mm, inset bars = 100 μm.

Prostatic Mucinous Cysts

This noninvasive lesion (see Figures 4–6) is characterized by dilated acini filled with pale amphophilic mucinous material and a small amount of debris surrounded by dense fibrous connective tissue and inflammatory cells. The size and appearance of the cysts vary. The epithelial lining for individual cystic acini is metaplastic and varies from hypercellular columnar cells producing mucin to low columnar and atrophic squamoid cells. These different types of epithelial cells occur adjacent to each other. Localized areas of mucosal denudation may be present. We noted that mucinous cysts appeared only in the dorsolateral lobe and at a low incidence.

Prostatic Epithelial Degeneration

Distention of the cytoplasm of the prostatic epithelium and pale eosinophilic staining typify this lesion (Figure 7). The nuclei are shrunken and have lost polarity. Occasionally there is autophagy or phagocytosis of the epithelial cells by the macrophages between them. We observed that epithelial degeneration occurred more frequently in the ventral than the dorsolateral lobe.

Seminal Vesicular Dilatation

The lumen is filled with secretion and shows great distention associated with thinning of the muscular wall and flattening of the epithelium. We rarely observed this change, and the severity of this lesion was estimated by the degree of dilatation.

Prostatic, Coagulating Glandular, and Seminal Vesicular Edema

A distended interstitium contains faintly eosinophilic material. Few inflammatory cells are observed either in interstitia or acini (Figure 8). We observed a low frequency of edema in the different lobes of the prostate, coagulating gland and seminal vesicle; the severity of this lesion was estimated by the degree of expansion of the interstitium.

Prostatic Epithelial Hyperplasia

Hyperplasia, defined also as atypical hyperplasia by Bosland et al (5–7), consists of a proliferation of epithelial cells occurring in a single acinus or several adjacent acini without distention of the acini or compression of the surrounding tissues (Figures 9 and 10). Gradual transitions

TABLE 2.—Incidence of histopathological lesions.

Laboratory	A	B	C	D	Total
Number of studies	20	5	5	5	35
Number of animals	1,003	253	260	252	1,768
Dosing day	53–857	25–732	151–734	113–736	25–857
Dorsolateral lobe	(969)	(246)	(26)	(142)	(1383)
Edema	4 (0.4%)	0 (0.0%)	0 (0.0%)	0 (0.0%)	4 (0.3%)
	[3.5]	[ND]	[ND]	[ND]	[3.5]
Epithelial degeneration	96 (9.9%)	14 (5.7%)	6 (23.1%)	15 (10.6%)	131 (9.5%)
	[1.6]	[1.5]	[1.3]	[1.3]	[1.5]
Inflammation	655 (67.6%)	197 (80.1%)	21 (80.8%)	101 (71.1%)	974 (70.4%)
	[1.9]	[1.8]	[1.5]	[1.8]	[1.9]
Mucinous cysts	59 (6.1%)	15 (6.1%)	0 (0.0%)	5 (3.5%)	79 (5.7%)
	[2.1]	[2.0]	[ND]	[2.2]	[2.1]
Primary tumor					
Schwannoma	1 (0.1%)	0 (0.0%)	0 (0.0%)	0 (0.0%)	1 (0.1%)
Secondary tumors	29 (3.0%)	11 (4.5%)	3 (11.5%)	1 (0.7%)	44 (3.2%)
Ventral lobe	(524)	(82)	(242)	(190)	(1038)
Edema	1 (0.2%)	0 (0.0%)	2 (0.8%)	0 (0.0%)	3 (0.3%)
	[2.0]	[ND]	[2.0]	[ND]	[2.0]
Epithelial degeneration	197 (37.6%)	5 (6.1%)	83 (34.3%)	40 (21.1%)	325 (31.3%)
	[1.4]	[1.4]	[1.5]	[1.3]	[1.4]
Inflammation	52 (9.9%)	3 (3.7%)	30 (12.4%)	13 (6.8%)	98 (9.4%)
	[2.0]	[1.0]	[2.0]	[1.8]	[1.9]
Epithelial hyperplasia	42 (8.0%)	4 (4.9%)	44 (18.2%)	17 (8.9%)	107 (10.3%)
Primary tumor					
Adenoma	4 (0.8%)	0 (0.0%)	3 (1.2%)	2 (1.1%)	9 (0.9%)
Secondary tumors	9 (1.7%)	0 (0.0%)	14 (5.8%)	8 (4.2%)	31 (3.0%)
Coagulating gland	(850)	(202)	(212)	(224)	(1488)
Edema	5 (0.6%)	0 (0.0%)	0 (0.0%)	0 (0.0%)	5 (0.3%)
	[2.8]	[ND]	[ND]	[ND]	[2.8]
Inflammation	9 (1.1%)	3 (1.5%)	0 (0.0%)	2 (0.9%)	14 (0.9%)
	[2.9]	[4.0]	[ND]	[3.0]	[3.1]
Secondary tumors	6 (0.7%)	1 (0.5%)	2 (0.9%)	4 (1.8%)	13 (0.9%)
Seminal vesicle	(993)	(252)	(256)	(248)	(1749)
Dilatation	4 (0.4%)	1 (0.4%)	0 (0.0%)	2 (0.8%)	7 (0.4%)
	[3.5]	[4.0]	[ND]	[4.0]	[3.7]
Edema	5 (0.5%)	0 (0.0%)	0 (0.0%)	0 (0.0%)	5 (0.3%)
	[3.0]	[ND]	[ND]	[ND]	[3.0]
Inflammation	8 (0.8%)	6 (2.4%)	0 (0.0%)	5 (2.0%)	19 (1.1%)
	[2.6]	[2.7]	[ND]	[2.6]	[2.6]
Epithelial hyperplasia	2 (0.2%)	2 (0.8%)	1 (0.4%)	0 (0.0%)	5 (0.3%)
Primary tumor					
Adenoma	1 (0.1%)	0 (0.0%)	0 (0.0%)	0 (0.0%)	1 (0.1%)
Secondary tumors	72 (7.3%)	33 (13.1%)	17 (6.6%)	12 (4.8%)	134 (7.7%)
Ampullary gland	(632)	(222)	(8)	(69)	(931)
Inflammation	147 (23.3%)	37 (16.7%)	2 (25.0%)	8 (11.6%)	194 (20.8%)
	[1.1]	[1.2]	[1.0]	[1.0]	[1.1]
Secondary tumors	9 (1.4%)	0 (0.0%)	0 (0.0%)	0 (0.0%)	9 (1.0%)

( ): Number of animals with available tissue for evaluation.
(%): Percentage of total number of animals.
[ ]: Mean severity of nonproliferative histopathological lesions.
[ND]: Not detected.
Nonproliferative lesions were scored using 4 semiquantitative grades as follows: 1—minimal, 2—mild, 3—moderate, 4—marked; mean severities are based on affected animals only.

occur from normal epithelium to hyperplastic areas with papillary and cribriform formation. No inflammatory reaction in or around this lesion is seen. No capsule formation is observed. Hyperplastic epithelium is generally columnar, and cytoplasm is tinctorially similar to that of normal epithelium. Cellular polarity tends to be lost, and mitotic figures are rarely observed. Reactive hyperplasia associated with inflammation is considered a component of the inflammatory lesion and not recorded as a separate finding as suggested by Bosland et al (5–7). Cases of functional hyperplasia described by Bosland et al (5–7) and characterized by increased infolding of the epithelium at the periphery of the lobes are not included. In our investigation, epithelial hyperplasia was observed at low incidence only in the ventral lobe.

Seminal Vesicular Epithelial Hyperplasia

Hyperplasia is defined as a proliferation of epithelial cells without distention of the acini or compression of the surrounding tissues (Figure 11). Gradual transitions occur from normal epithelium to hyperplastic areas with papillary formation. No inflammatory reactions in or around this lesion are seen. Hyperplastic epithelial cells are generally columnar and contain much more cytoplasm than normal epithelium. Cellular polarity tends to be lost, and nuclei are hyperchromatic. Mitotic figures are rarely observed. We rarely encountered epithelial hyperplasia in the seminal vesicle.

Prostatic Adenoma

Adenoma (Figures 12 and 13) is defined as an intraglandular epithelial proliferation filling the lumen of one or more adjacent acini. No inflammation is associated with adenomas, but in some lesions foamy macrophages are seen. Distortion or compression of surrounding tissue is observed. The epithelial cells are usually arranged in a cribriform or papillary pattern. The cells are cuboidal to columnar and slightly eosinophilic. The nuclei are round and slightly

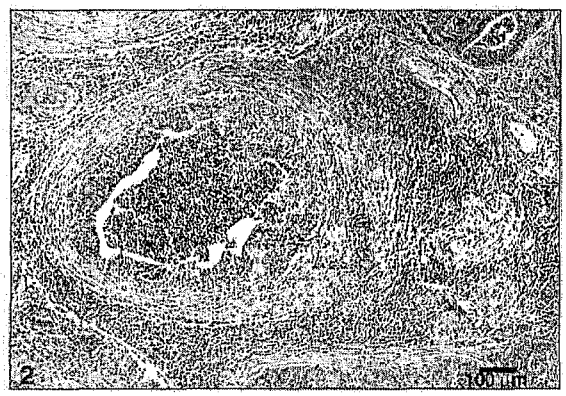
2
100 µm

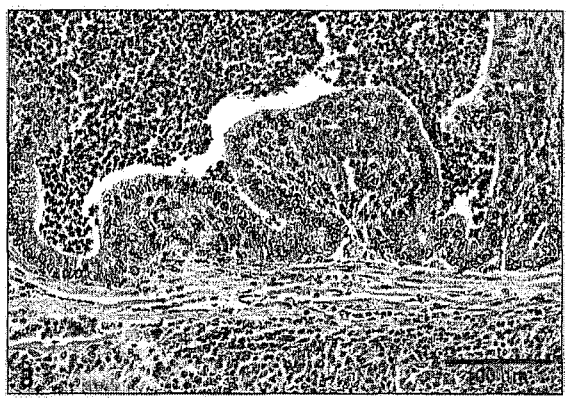
3
100 µm

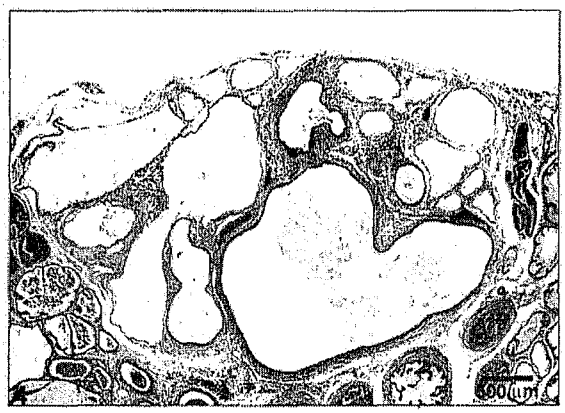
4
500 µm

5
100 µm

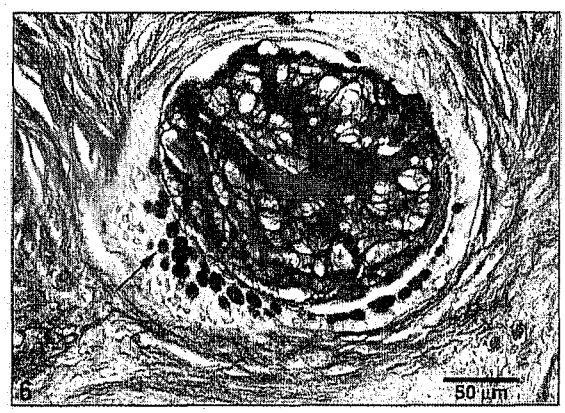
6
50 µm

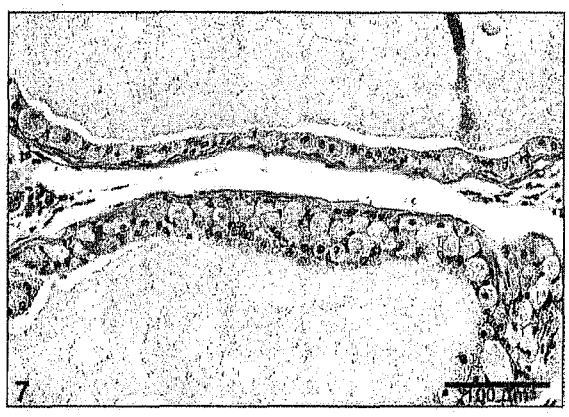
7
100 µm

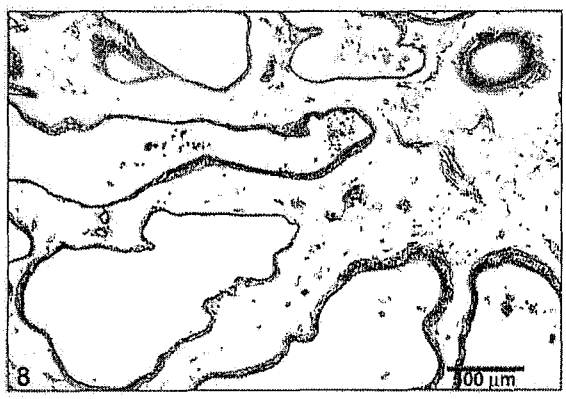
8
500 µm

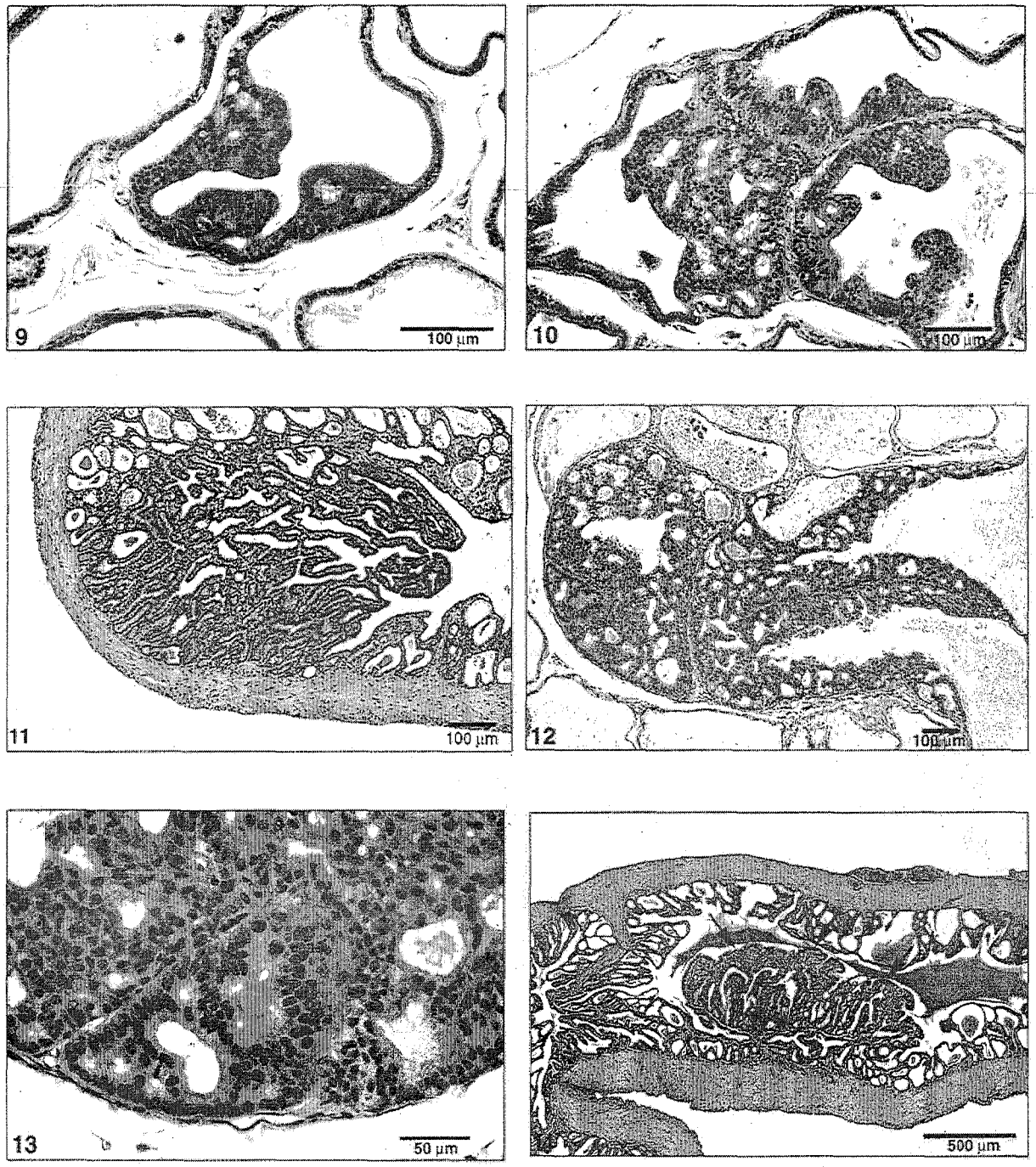

FIGURE 2.—Marked (grade 4) inflammation in the dorsolateral lobe. Accumulation of neutrophils in the acinar lumen and increase in connective tissue with lymphocytic infiltration in the interstitium are prominent. H&E stain. Bar = 100 μm. 3.—Marked (grade 4) inflammation in the dorsolateral lobe. Note reactive hyperplasia of the epithelium. H&E stain. Bar = 100 μm. 4.—Moderate (grade 3) mucinous cysts in the dorsolateral lobe are surrounded by fibrous tissue and distended into various sizes by pale amphophilic material. H&E stain. Bar = 500 μm. 5.—Moderate (grade 3) mucinous cysts in the dorsolateral lobe are surrounded by fibrous tissue and lined by columnar to squamoid cells. Masson-trichrome stain. Bar = 100 μm. 6.—Moderate (grade 3) mucinous cysts in the dorsolateral lobe. Metaplastic columnar epithelial cells have PAS-positive (arrow) or Alcian blue-positive material. Alcian blue (pH 2.5)-PAS stain. Bar = 50 μm. 7.—Mild (grade 2) epithelial degeneration in the ventral lobe. Epithelial cells are distended by pale eosinophilic material. The nuclei are located peripherally. H&E stain. Bar = 100 μm. 8.—Mild (grade 2) edema in the ventral lobe. Faintly eosinophilic material is present in the interstitium. H&E stain. Bar = 500 μm. 9.—Focal intra-acinar epithelial hyperplasia in the ventral lobe. Note cribriform and papillary growth into the lumen. H&E stain. Bar = 100 μm. 10.—Epithelial hyperplasia in the ventral lobe. Note minimal cribriform and papillary growth. H&E stain. Bar = 100 μm. 11.—Epithelial hyperplasia in the seminal vesicle. Note papillary growth. H&E stain. Bar = 100 μm. 12.—Adenoma in the ventral lobe. The tumor is compressing the surrounding tissue. A cribriform growth pattern is prominent. H&E stain. Bar = 100 μm. 13.—Higher magnification of Figure 12. Epithelial cells have lost their polarity, and nuclear pleomorphism is shown. H&E stain. Bar = 50 μm. 14.—Adenoma in the seminal vesicle. The neoplastic epithelium has formed as a papillary bud (arrows) extending into the lumen. H&E stain. Bar = 500 μm.

TABLE 3.—Summary of pituitary gland adenoma and prostatic inflammation incidence and severity in male F-344 control rats in 5 NTP studies.

Reference	Incidence of pituitary gland adenoma	Incidence of inflammation		Severity of inflammation (Mean)**	
		Dorsolateral lobes	Ventral lobes	Dorsolateral lobes	Ventral lobes
37	38.0% (19/50)	70.8% (34/48)	18.4% (9/49)	1.4	0.4
34	40.0% (20/50)	84.0% (42/50)	18.0% (9/50)	1.9	0.4
36*	31.7% (19/60)	78.3% (47/60)	8.5% (5/59)	1.5	0.2
33	20.0% (10/50)	73.5% (36/49)	8.5% (4/47)	1.5	0.2
35	28.0% (14/50)	48.9% (23/47)	16.7% (8/48)	0.9	0.3

*Lifetime study; others were 2-year studies.
**Including studies having zero severity.

hyperchromatic. Cells have lost their normal polarity, and mitotic figures are occasionally seen. The basement membrane of the adenomatous acini remains intact. We observed that adenoma in the prostate was mostly confined to the ventral lobe.

Seminal Vesicular Adenoma

Gradual transitions occur from normal epithelium to proliferative areas (Figure 14). No inflammatory reactions in or around this lesion are seen. The epithelial cells are predominantly arranged in a cribriform or papillary pattern. The epithelial cells are generally columnar and contain much more cytoplasm than normal epithelium. Cellular polarity tends to be lost, and nuclei are hyperchromatic. Mitotic figures are rarely observed. The one adenoma that we observed was characterized by a proliferation of epithelial cells with peduncular attachment.

Statistical Analysis of the Relationship Between Prostatic Inflammation and Pituitary Gland Adenoma, Epithelial Hyperplasia, and Mucinous Cysts

Inflammation of the ventral lobe occurred at a much lower incidence and severity than in the dorsolateral lobes (Table 3) and showed no correlation with the incidence of pituitary gland adenoma. In contrast, the incidence and severity of inflammation in the dorsolateral lobes of prostate showed a highly significant ($p < 0.001$) association with the presence of pituitary adenomas (Table 4). No association was found between prostatic inflammation and the incidence of hyperplasia in the ventral or dorsolateral lobe (data not presented). Multiple and logistic regression analyses revealed a significant ($p < 0.05$) association between inflammation and mucinous cysts in the dorsolateral lobes (Table 5).

Immunohistochemical Expression of Pituitary Gland Adenoma

Most pituitary gland adenomas demonstrated PRL positivity, and most PRL-positive pituitary gland adenomas were accompanied by inflammation of the dorsolateral prostatic lobe (Table 6). One PRL-positive pituitary gland adenoma had TSH and LH positivity. TSH and LH positivity, but PRL negativity, were observed in one pituitary gland adenoma. ACTH positivity was detected in one adenoma; no other hormonal reactivity was observed.

DISCUSSION

Comparison of histopathological findings from the 4 laboratories revealed that the recorded incidence of proliferative lesions and epithelial degeneration in the ventral lobes was higher in laboratories that sampled primarily the ventral lobe, whereas recorded observation of inflammation and mucinous cysts in the dorsolateral lobe was higher from laboratories that sampled mainly dorsolateral lobes. These results indicate obvious sampling bias and suggest the importance of histopathological examination of both dorsolateral and ventral lobes of rat prostate to detect proliferative as well as nonproliferative lesions.

Although the coagulating glands and seminal vesicles obtained from the 4 laboratories were sectioned optimally, sectioning of both dorsolateral and ventral lobes was not consistent. Because of anatomical similarities of the human prostatic posterior, middle, and lateral lobes to the rat dorsal, anterior (coagulating gland) and lateral lobes, respectively (48), inclusion of both dorsolateral and ventral lobes in histopathological examinations to determine precise lobe localization of lesions in rat prostate might have relevance to humans.

TABLE 4.—Summary of association between incidence of pituitary gland adenoma and prostatic inflammation in dorsolateral lobes in male F-344 control rats from 5 NTP studies.

Severity of inflammation in dorsolateral lobes	Incidence of pituitary gland adenoma	Survival time (days) (Mean ± SD)
0	15.3% (11/72)	693 ± 96
1	14.8% (9/61)	676 ± 128
2	41.2% (28/68)*	685 ± 82
3	56.8% (25/44)*	673 ± 83
4	88.9% (8/9)*	666 ± 71

*$p < 0.05$ versus animals with no inflammation; overall trend: $p < 0.001$.

TABLE 5.—Summary of association between incidence and severity of mucinous cysts and prostatic inflammation in dorsolateral lobes in male F-344 control rats from 5 NTP studies.

Severity of inflammation	Mucinous cysts	
	Incidence	Severity* (Mean)
0	1.4% (1/72)	0.0
1	6.6% (4/61)	0.1
2	8.8% (6/68)	0.2
3	9.1% (4/44)	0.2
4	22.2% (2/9)	0.6

*Significance of overall trend $p < 0.05$, including studies having zero severity.

TABLE 6.—Summary of immunohistochemical expression of 15 (3/study, selected at random) pituitary gland adenomas and their association with prostatic inflammation*.

	PRL	GH	TSH	LH	ACTH
Total number of immuno-positive pituitary gland adenomas	13/15 (86.7%)	0/15 (0.0%)	2/15 (13.3%)	2/15 (13.3%)	1/15 (6.7%)
Number of pituitary gland adenomas with inflammation in dorsolateral lobe	12/13 (92.3%)	0/0 (—)	2/2 (100.0%)	2/2 (100.0%)	1/1 (100.0%)
Number of pituitary gland adenomas without inflammation in dorsolateral lobe	1/13 (7.7%)	0/0 (—)	0/2 (0.0%)	0/2 (0.0%)	0/1 (0.0%)
Number of pituitary gland adenomas with inflammation in ventral lobe	2/13 (15.4%)	0/0 (—)	0/2 (0.0%)	0/2 (0.0%)	0/1 (0.0%)
Number of pituitary gland adenomas without inflammation in ventral lobe	11/13 (84.6%)	0/0 (—)	2/2 (100.0%)	2/2(100.0%)	1/1 (100.0%)

(%), Percentage of number of pituitary gland adenomas expressing immunohistochemical positivity.
PRL: prolactin; GH: growth hormone; TSH: thyroid-stimulating hormone; LH: luteinizing hormone; ACTH: adrenocorticotrophic hormone.
*13/15 cases had inflammation in the dorsolateral lobe and 2/15 cases had inflammation in the ventral lobe.

The association between the quantity of tissue present in a section and the incidence of prostatic lesions is illustrated in Table 7 using epithelial degeneration of the ventral lobe as an example. Note that the incidence of this degeneration is clearly related to the amount of tissue present at Laboratories A, C, and D; Laboratory B had an insufficient quantity of tissue to show this association. For example, the 3 to 4-fold increase in the overall incidence of epithelial degeneration of ventral prostate at Laboratory D (21%) relative to Laboratory B (6%) is highly significant ($p < 0.01$ by a Fisher's exact test) (47) if the amount of tissue sampled is not taken into account. If tissue amount is considered, however, by comparing incidence rates for groups with equivalent tissue amounts using a Mantel–Haenszel test (49), then the difference in incidences between the two laboratories becomes insignificant ($p > 0.20$). The reason that the incidence of epithelial degeneration of the ventral lobe is much lower in Laboratory B (6%) than at the other 3 laboratories (21–38%) likely simply reflects the fact that 79% (65/82) of the ventral lobe samples at this laboratory involved only 1–25% of the lobe. In contrast, 80–98% of the samples from the other 3 laboratories involved 26–100% of the lobe, so a higher incidence of epithelial degeneration would be expected and was observed. The amount of tissue sampled by a laboratory clearly influences the reported incidence of epithelial degeneration of the ventral lobe. These observations illustrate that the quantity of tissue sampled is an important variable that must be standardized if historical control incidence data from different laboratories are to be compared.

The histopathological characteristics of spontaneous proliferative and nonproliferative lesions in prostate and seminal vesicles of F-344 rats compiled for this study were similar to those previously reported for this and other rat strains (4, 18, 30, 50). Quantification of the incidence and characterization of proliferative and nonproliferative lesions in each lobe of the prostate, seminal vesicle and ampullary gland is important because of differential lobe sensitivity to spontaneous and induced lesions (4–7, 22).

Although less tissue from the ventral than the dorsolateral lobe was present in slides from all four laboratories, our findings demonstrate that proliferative lesions of the rat prostate, including epithelial hyperplasia and adenoma, were limited exclusively to the ventral lobes. Spontaneous proliferative lesions are known to occur more frequently in ventral than dorsolateral lobes, while chemical carcinogens induce neoplastic changes predominately in the dorsolateral lobe (4–6, 22, 30, 41). As reported previously (30, 41), no spontaneously occurring adenocarcinoma was seen in ventral lobes of F-344 rats. Adolescent F-344 rats have been shown to be resistant to epithelial hyperplasia of the ventral lobe compared to Wistar and Sprague-Dawley rats exposed to tumor promoters during the ontogenetic and postcastration growth and differentiation periods (44). This interstrain susceptibility was suggested to be related to a possible decreased sensitivity of androgen receptors in F-344 rats (44). Epithelial hyperplasia and adenoma, as well as adenocarcinoma, are rarely reported in the seminal vesicle in the F-344 rat (22, 30, 46); similar findings were observed in the present investigation. Spontaneous proliferative lesions including hyperplasia and adenoma have not been reported in the ampullary gland in rats (7).

In the male accessory sex glands, inflammation is frequently seen in prostatic tissue of the rat (4, 6). Spontaneous prostatitis occurs in the lateral lobe of aged rats and has been used as a model of nonbacterial prostatitis in humans (2, 29, 31). In our study, histopathological features of inflammation in the dorsolateral lobes were similar to those described for various strains of rats used for toxicity and carcinogenicity

TABLE 7.—Incidence of epithelial degeneration in ventral lobe as a function of amount of tissue examined.

Quantity of tissue	Laboratory A	Laboratory B	Laboratory C	Laboratory D	Total
1–25%	9% (9/105)	6% (4/65)	17% (1/6)	0% (0/19)	7% (14/195)
26–50%	36% (37/104)	7% (1/14)	32% (25/79)	20% (14/71)	29% (77/268)
51–75%	48% (70/145)	0% (0/2)	28% (22/79)	24% (11/46)	38% (103/272)
76–100%	48% (81/170)	0% (0/1)	45% (35/78)	28% (15/54)	43% (131/303)
Total	38% (197/524)	6% (5/82)	34% (83/242)	21% (40/190)	31% (325/1038)

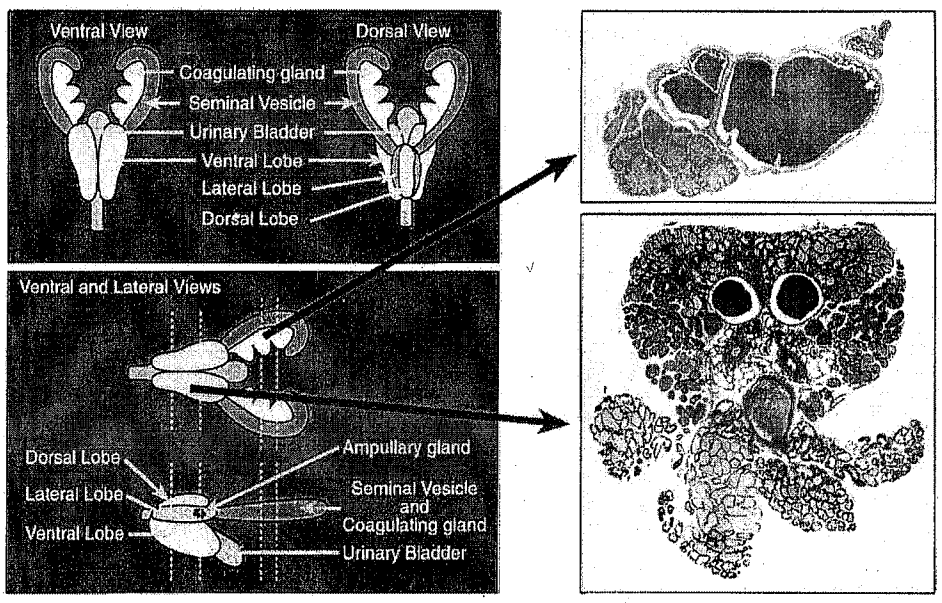

FIGURE 15.—Proposal for histological trimming of rat prostate and seminal vesicle. A midtransverse section should be made by making a midtransverse cut of 2–3 mm in thickness at mid area of ventral lobes that corresponds to region obscuring urinary bladder; embed anterior side of posterior portion of prostate downward for microscopic examination of this cut surface to include dorsal, lateral, and ventral lobes and ampullary gland; midtransverse section of seminal vesicle and coagulating gland should be made at mid area of seminal vesicle.

studies (2, 4, 6, 8, 12, 31, 39). Bacterial infection (6, 31, 39), endocrine influence (6, 24, 29, 39, 42, 51, 52), immunological dysfunction (13, 38, 39), and stress (1, 6, 17) may be factors in development of prostatic inflammation. Because chronic inflammation of the prostate was suggested to promote hyperplasia in this tissue (25), we examined the possible relationship between these two processes in our study and found no clear association.

Neonatal hyperprolactinemia induced by estradiol or PRL can later result in inflammation in the lateral prostate of the adult rat with histopathological features similar to those of spontaneous inflammation in the lateral lobe in rats (42, 53). Recently, hyperprolactinemia in the adult male rat has been implicated in the development of prostatitis of the lateral lobes (40, 42, 51, 52). A dose-response relationship between exogenous prolactinemia and the severity of lateral prostatic inflammation was observed (53). Because hyperprolactinemia or manipulation of PRL can either enhance or suppress humoral and cellular immune responses, inflammation in the lateral lobe may be related to an altered immune function (32, 52). PRL is likely involved because the lateral lobes appear more sensitive than the other 3 lobes to the action of this hormone (6). The majority of spontaneous pituitary gland adenomas, relatively common among F-344 rats, are immunohistochemically reactive for PRL (43). Pituitary gland adenomas of aging rats show mammotrophic or mammosomatotrophic functions, and rats with mammotrophic neoplasms have elevated serum PRL activity (9, 15). Although no statistical analysis was performed due to small sample size, our limited immunohistochemical investigation showed that PRL-positive adenomas were the most common finding (13/15 cases) in the pituitary gland. Twelve of these cases were associated with inflammation in the dorsolateral prostatic lobe. In contrast, in 2 of these animals showing 13 adenomas positive for PRL, inflammation of the prostate ventral lobe was noted. The significant relationship between the severity of inflammation in the dorsolateral lobes and the incidence of pituitary gland adenoma and immunohistochemical findings in this study suggests that excess PRL produced by a pituitary gland adenoma may be a predisposing factor for inflammation in the dorsolateral lobes.

Mucinous cysts, a lesion in the dorsolateral lobes in this study, have been referred to as mucoid metaplasia or cystic changes in rat prostate (6). Differentiating between mucinous metaplasia and prostatic carcinoma is important because some histological features of mucinous metaplasia resemble those of low-grade prostatic carcinoma (45). Mucinous metaplasia occurs mainly in periurethal areas of human prostate and is associated with an embryological remnant resembling the prostatic utricle (16). The association of mucinous cysts and inflammation in the dorsolateral lobe in our study suggests that chronic irritation such as inflammation could be a causative factor.

Epithelial degeneration, the most common lesion that we observed in the ventral lobes, had histopathologic features similar to those reported previously (3, 4, 6, 29). The decline of androgenic hormone by castration has been reported to induce prostatic epithelial degeneration, leading to both autophagy and phagocytosis of the epithelial cells by macrophages (4, 29). The frequency of this lesion in the dorsolateral and ventral lobes suggests sensitivity of these lobes to androgen withdrawal (3).

Other histopathological lesions including edema in the dorsolateral and ventral lobes, coagulating gland and seminal vesicle; dilatation in seminal vesicle; and secondary tumors metastasizing in the dorsolateral and ventral lobes, coagulating glands, seminal vesicles, and ampullary glands appear to have unrelated causes (4, 6).

The conclusion from our survey is that greater attention should be given to optimal technical sampling of prostate. Although ventral lobes have, in the past, been collected and embedded separately from the dorsolateral lobes for various reasons, eg, weighing (7), we recommend that the collection and fixation of prostate, seminal vesicle, and urinary bladder be achieved together as a unit in order to maintain anatomic relationships for histopathological examination. Trimming should be performed to include both dorsolateral and ventral lobes as shown in Figure 15 (5, 7). We recommend that examiners make a midtransverse cut of 2–3 mm in thickness at the mid area of the ventral lobes. This anterior face of the posterior portion of the prostate should correspond to the prostatic region that obscures the base of the urinary bladder. This cut surface is then embedded downward for microscopic examination. We found that transverse sectioning was superior to frontal sectioning for yielding the optimal amount of prostate examined in a single section. Consistent collection of all appropriate regions by proper trimming and embedment is essential to ensure accurate histopathological diagnoses of prostatic lesions.

Acknowledgments

The authors are grateful to JoAnne Johnson of the National Institute of Environmental Health Sciences; Peter B. Little of Pathology Associates International, Inc; and Sundeep Chandra of Experimental Pathology Laboratories, Inc, for their helpful comments. The authors thank William C. Hall of Pathology Associates International, Inc. for his assistance with immunohistochemical examination and Norris Flagler of the National Institute of Environmental Health Sciences for his assistance with the photography.

References

1. Aronsson A, Dahlgren S, Gatenbeck L, Stromberg L (1988). Predictive sites of inflammatory manifestation in the prostatic gland: An experimental study on nonbacterial prostatitis in the rat. *Prostate* 13: 17–24.
2. Aumüller G, Enderle-Schmitt U, Seitz J, Müntzing J, Chandler JA (1987). Ultrastructure and immunohistochemistry of the lateral prostate in aged rats. *Prostate* 10: 245–256.
3. Aumüller G, Sinowatz F (1992). Normal development, growth, and aging in the male accessory sex glands. In: *Pathobiology of the Aging Rat, vol 1*, Mohr U, Dungworth DL, Capen CC (eds). ILSI Press, Washington DC, pp 427–442.
4. Boorman GA, Elwell MR, Mitsumori K (1990). Male accessory sex glands, penis, and scrotum. In: *Pathology of Fischer Rats*, Boorman GA, Eustis SL, Elwell MR, Montgomery Jr CA, MacKenzie WF (eds). Academic Press, San Diego, pp 419–428.
5. Bosland MC (1987). *Monographs on Pathology of Laboratory Animals, Genital System*, Jones TC, Mohr U, Hunt RD (eds). Springer-Verlag, Berlin, pp 252–275.
6. Bosland MC (1992). Lesions in the male accessory sex glands and penis. In: *Pathobiology of the Aging Rat, vol 1*, Mohr U, Dungworth DL, Capen CC (eds). ILSI Press, Washington, DC, pp 443–467.
7. Bosland MC, Tuomari DL, Elwell MR, Shirai T, Ward JM, McConnell RF (1998). Proliferative lesions of the prostate and other accessory sex glands in male rats. In: *Guides for Toxicologic Pathology*, STP/ARP/AFIP, Washington, DC, pp 1–20.
8. Burek JD (1983). Age-associated pathology. In: *Pathology of Aging Rats*, CRC Press, Boca Raton, FL, pp 29–168.
9. Carlton WW, Gries CL (1996). Adenoma and carcinoma, pars distalis, anterior pituitary gland, rat. In: *Monographs on pathology of laboratory animals, Endocrine system, 2nd ed*, Jones TC, Capen CC, Mohr U (eds). Springer-Verlag, Berlin, pp 71–82.
10. Chhabra RS, Huff JE, Schwetz BS, Selkirk J (1990). An overview of prechronic and chronic toxicity/carcinogenicity experimental study designs and criteria used by the National Toxicology Program. *Environ Health Perspect* 86: 313–321.
11. Coleman GL, Barthold W, Osbaldiston GW, Foster SJ, Jonas AM (1977). Pathological changes during aging in barrier-reared Fischer 344 male rats. *J Gerontol* 32: 258–278.
12. Deerberg F, Rehm S (1981). Secondary inflammatory lesions of the urogenital organs in aging Han: WIST rats. *Z Versuchstierkd* 23: 73–76.
13. Depiante-Depaoli M, Pacheco-Rupil B (1985). Experimental autoimmunity to rat male accessory glands (MAG): Circulating antibodies, immunoglobulins bound to target glands, and immunoglobulins-secreting cells. *Am J Reprod Immunol Microbiol* 7: 32–38.
14. Dinse GE, Haseman JK (1986). Logistic regression analysis of incidental-tumor data from animal carcinogenicity experiments. *Fundam Appl Toxicol* 6: 44–52.
15. Furth J, Nakane PK, Pasteels JL (1976). Tumours of the pituitary gland. In: *Pathology of Tumours in Laboratory Animals, vol 1, part 2*, Turusov VS (ed). IARC scientific publication No. 6, IARC, Lyon, pp 201–237.
16. Gal R, Koren R, Nofech-Mozes S, Mukamel E, His Y, Zajdel L (1996). Evaluation of mucinous metaplasia of the prostate gland by mucin histochemistry. *Br J Urol* 77: 113–117.
17. Gatenbeck L, Aronsson A, Dahlgren S, Johansson B, Stromberg L (1987). Stress stimuli-induced histopathological changes in the prostate: An experimental study in the rat. *Prostate* 11: 69–76.
18. Goodman DG, Ward JM, Squire RA, Chu KC, Linhart MS (1979). Neoplastic and nonneoplastic lesions in aging F344 rats. *Toxicol Appl Pharmacol* 48: 237–248.
19. Hayashi N, Sugimura Y, Kawamura J, Donjacour AA, Cunha GR (1991). Morphological and functional heterogeneity in the rat prostatic gland. *Biol Reprod* 45: 308–321.
20. Holland JM, Lee C (1980). Effects of pituitary grafts on testosterone stimulated growth of rat prostate. *Biol Reprod* 22: 351–355.
21. Hsu SM, Raine L, Fanger H (1981). Use of avidin-biotin-peroxidase complex (ABC) in immunoperoxidase techniques: A comparison between ABC and unlabeled antibody (PAP) procedures. *J Histochem Cytochem* 29: 577–580.
22. Ito N, Shirai T (1990). Tumours of the accessory male sex organs. In: *Pathology of Tumours in Laboratory Animals, 2nd ed, vol 1*, Turusov VS, Mohr U (eds). IARC Scientific Publication No. 99, IARC, Lyon, pp 421–443.
23. Jesik CJ, Holland JM, Lee C (1982). An anatomic and histologic study of the rat prostate. *Prostate* 3: 81–97.
24. Kaplan L, Lee C, Schaeffer AJ (1983). Effect of castration on experimental bacterial prostatitis in rats. *Prostate* 4: 625–630.
25. Kessler OJ, Keisari Y, Servadio C, Abramovici A (1998). Role of chronic inflammation in the promotion of prostatic hyperplasia in rats. *J Urol* 159: 1049–1053.
26. Lee C (1981). Physiology of castration-induced regression in rat prostate. In: *The Prostatic Cell: Structure and Function, Part A: Morphologic, Secretory, and Biochemical Aspects*, Murphy GP, Sandberg AA, Karr JP (eds). Liss, New York, pp 145–159.
27. Lee C (1987). Gross dissection of three lobes of the rat prostate. *Prog Clin Biol Res* 239: 577–582.
28. Lee C, Holland JM (1987). Anatomy, histology, and ultrastructure (correlation with function), prostate, rat. In: *Monographs on Pathology of Laboratory Animals, Genital System*, Jones TC, Mohr U, Hunt RD (eds). Springer-Verlag, Berlin, pp 239–251.
29. Lundgren R, Holmquist B, Hesselvik M, Müntzing J (1984). Treatment of prostatitis in the rat. *Prostate* 5: 277–284.
30. Mitsumori K, Elwell MR (1988). Proliferative lesions in the male reproductive system of F344 rats and B6C3F1 mice: Incidence and classification. *Environ Health Perspect* 77: 11–21.
31. Müntzing J, Sufrin G, Murphy GP (1979). Prostatitis in the rat. *Scand J Urol Nephrol* 13: 17–22.
32. Nagy E, Berczi I (1986). Immunomodulation by tamoxifen and pergolide. *Immunopharmacology* 12: 145–153.

33. National Toxicology Program (NTP) (1997). *Toxicology and Carcinogenesis Studies of Butyl Benzyl Phthalate (CAS No. 85-68-7) in F344/N Rats (Feed Studies)*, NTP technical report No. 458, NIH Publication No. 97-3374. US Department of Health and Human Services, Public Health Service, NIH, NIEHS, Research Triangle Park, NC.
34. National Toxicology Program (NTP) (1997). *Toxicology and Carcinogenesis Studies of D&C Yellow No. 11 (CAS No. 8003-22-3) in F344/N Rats (Feed Studies)*, NTP technical report No. 463, NIH Publication No. 97-3379. US Department of Health and Human Services, Public Health Service, NIH, NIEHS, Research Triangle Park, NC.
35. National Toxicology Program (NTP) (1997). *Toxicology and Carcinogenesis Studies of Salicylazosulfapyridine (CAS No. 599-79-1) in F344/N Rats and B6C3F$_1$ Mice (Gavage Studies)*, NTP technical report No. 457, NIH Publication No. 97-3373. US Department of Health and Human Services, Public Health Service, NIH, NIEHS, Research Triangle Park, NC.
36. National Toxicology Program (NTP) (1997). *Toxicology and Carcinogenesis Studies of t-Butylhydroquinone (CAS No. 1948-33-0) in F344/N Rats and B6C3F$_1$ Mice (Feed Studies)*, NTP technical report No. 459, NIH Publication No. 97-3375. US Department of Health and Human Services, Public Health Service, NIH, NIEHS, Research Triangle Park, NC.
37. National Toxicology Program (NTP) (1998). *Toxicology and Carcinogenesis Studies of Theophylline (CAS No. 58-55-9) in F344/N Rats and B6C3F$_1$ Mice (Feed and Gavage Studies)*, NTP technical report No. 473, NIH Publication No. 98-3963. US Department of Health and Human Services, Public Health service, NIH, NIEHS, Research Triangle Park, NC.
38. Pacheco-Rupil B, Depiante-Depaoli M, Casadio B (1984). Experimental autoimmune damage to rat male accessory glands. II. T cell requirement in adoptive transfer of specific tissue damage. *Am J Reprod Immunol* 5: 15–19.
39. Parker GA, Grabau J (1987). Chronic prostatitis, rat. In: *Monographs on Pathology of Laboratory Animals, Genital System*, Jones TC, Mohr U, Hunt RD (eds). Springer-Verlag, Berlin, pp 287–289.
40. Reiter E, Hennuy B, Bruyninx M, Cornet A, Klug M, McNamara M, Closset J, Hennen G (1999). Effects of pituitary hormones on the prostate. *Prostate* 38: 159–165.
41. Reznik G, Hamlin II MH, Ward JM, Stinson SF (1981). Prostatic hyperplasia and neoplasia in aging F344 rats. *Prostate* 2: 261–268.
42. Robinette CL (1988). Sex-hormone-induced inflammation and fibromuscular proliferation in the rat lateral prostate. *Prostate* 12: 271–286.
43. Sandusky GE, Van Pelt CS, Todd GC, Wightman K (1988). An immunocytochemical study of pituitary adenomas and focal hyperplasia in old Sprague-Dawley and Fischer 344 rats. *Toxicol Pathol* 16: 376–380.
44. Scolnik MD, Servadio C, Abramovici A (1994). Comparative study of experimentally induced benign and atypical hyperplasia in the ventral prostate of different rat strains. *J Androl* 15: 287–297.
45. Shiraishi T, Kusano I, Watanabe M, Yatani R, Liu PI (1993). Mucous gland metaplasia of the prostate. *Am J Surg Pathol* 17: 618–622.
46. Shoda T, Mitsumori K, Imazawa T, Toyoda K, Tamura T, Takada K, Takahashi M (1998). A spontaneous seminal vesicle adenocarcinoma in an aged F344 rat. *Toxicol Pathol* 26: 448–451.
47. Siegel S (1956). *Nonparametric Statistics for the Behavioral Sciences*. McGraw-Hill, New York.
48. Sikorski A (1982). Prostate lobes of aging rats: A morphometric light microscopic approach. *Folia Morphol (Warsz)* 41: 361–367.
49. Snedecor AW, Cochran WG (1980). *Statistical Methods, 7th ed.* Iowa State University Press, Ames, IA.
50. Solleveld HA, Haseman JK, McConnell EE (1984). Natural history of body weight gain, survival, and neoplasia in the F344 rat. *J Natl Cancer Inst* 72: 929–940.
51. Stoker TE, Robinette CL, Britt BH, Laws SC, Cooper RL (1999). Prepubertal exposure to compounds that increase prolactin secretion in the male rat: Effects on the adult prostate. *Biol Reprod* 61: 1636–1643.
52. Stoker TE, Robinette CL, Cooper RL (1999). Perinatal exposure to estrogenic compounds and the subsequent effects on the prostate of the adult rat: Evaluation of inflammation in the ventral and lateral lobes. *Reprod Toxicol* 13: 463–472.
53. Tangbanluekal L, Robinette CL (1993). Prolactin mediates estradiol-induced inflammation in the lateral prostate of Wistar rats. *Endocrinology* 132: 2407–2416.